

VULVAR DERMATOSES

Itching Burning Vulva

Vaginitis

Dermatoses

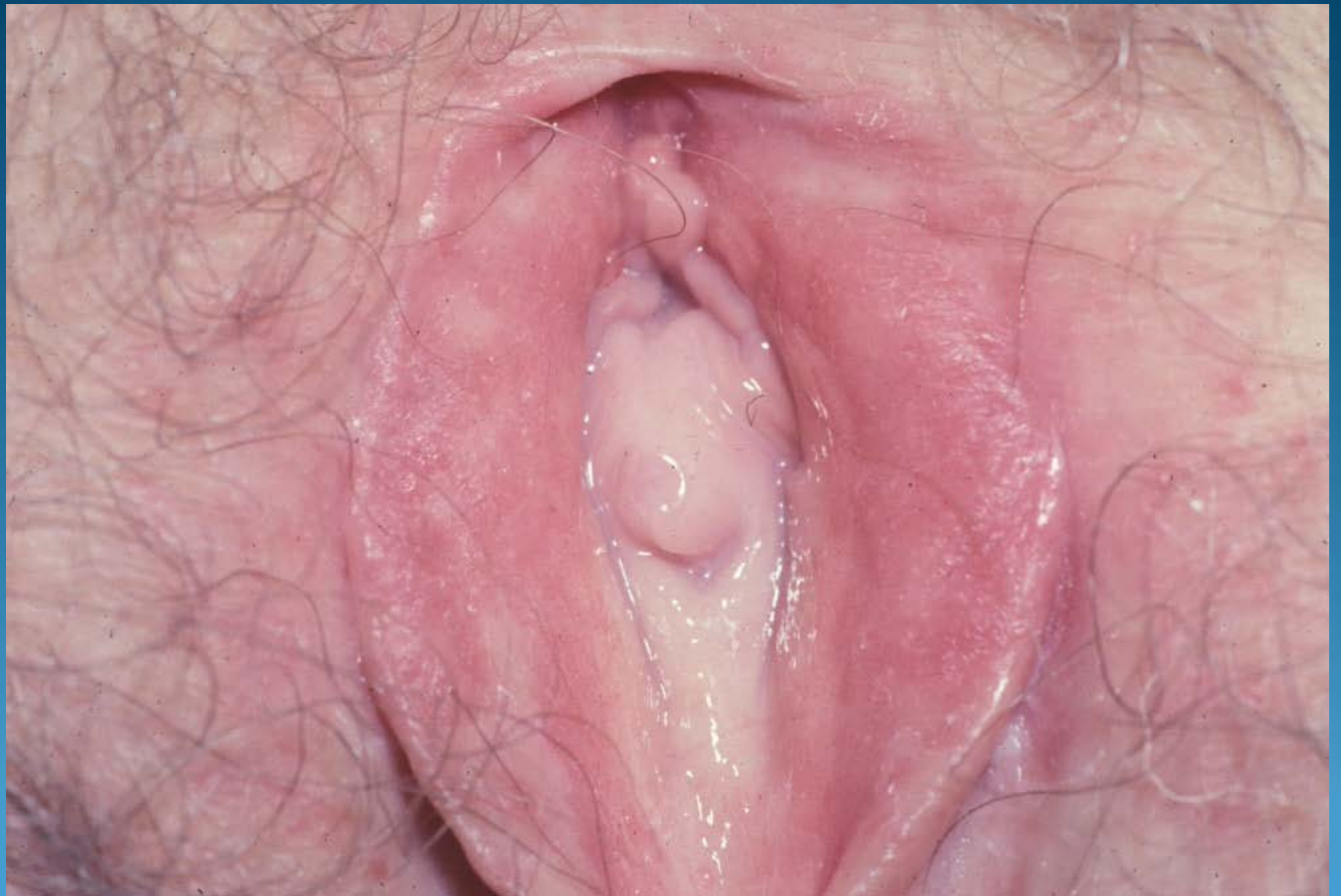Vulvodynia

Vaginal Disease

- Infectious vaginitis
- Atrophic vaginitis
- Cervicitis
- Vulvar intraepithelial dysplasias
- Etc!

Vulvar Dermatoses

- There are over 2000 different skin diseases and many of them can involve vulvar skin



“Do you itch or hurt?”

- Vulvar dermatoses usually ITCH
- If erosions are present, patients have PAIN

The “Three Lichens”

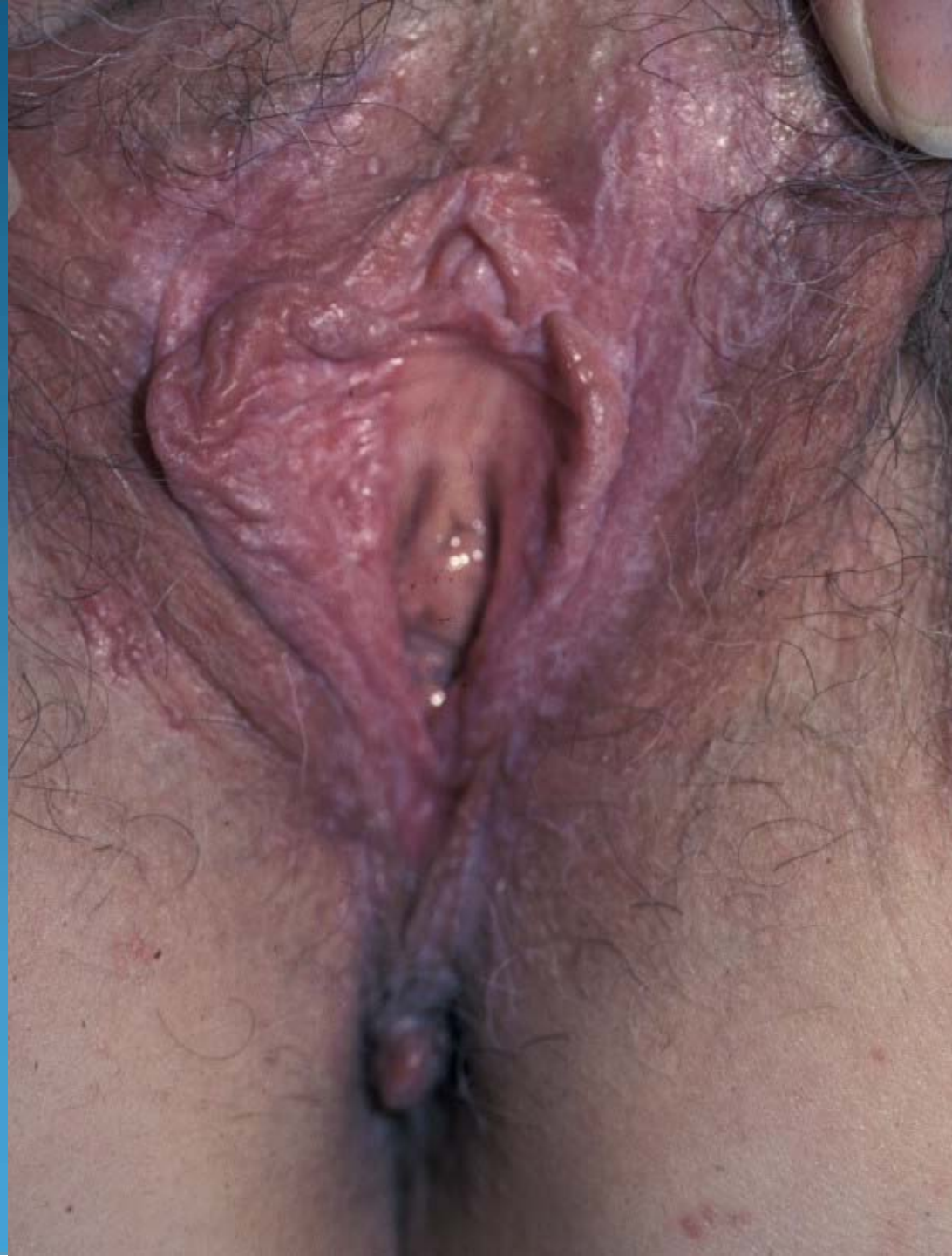- Lichen Planus
- Lichen Sclerosus
- Lichen Simplex Chronicus

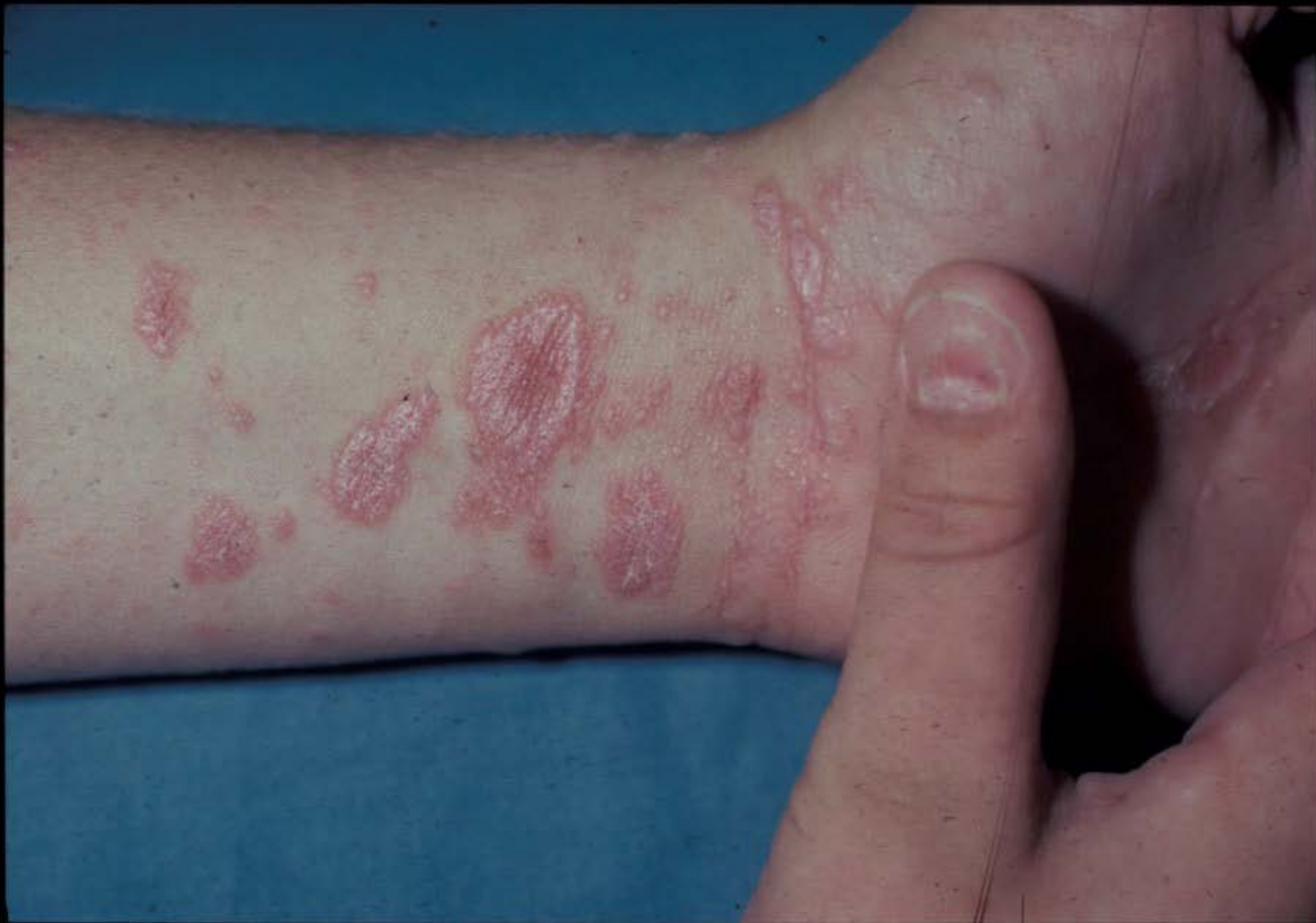LICHEN PLANUS

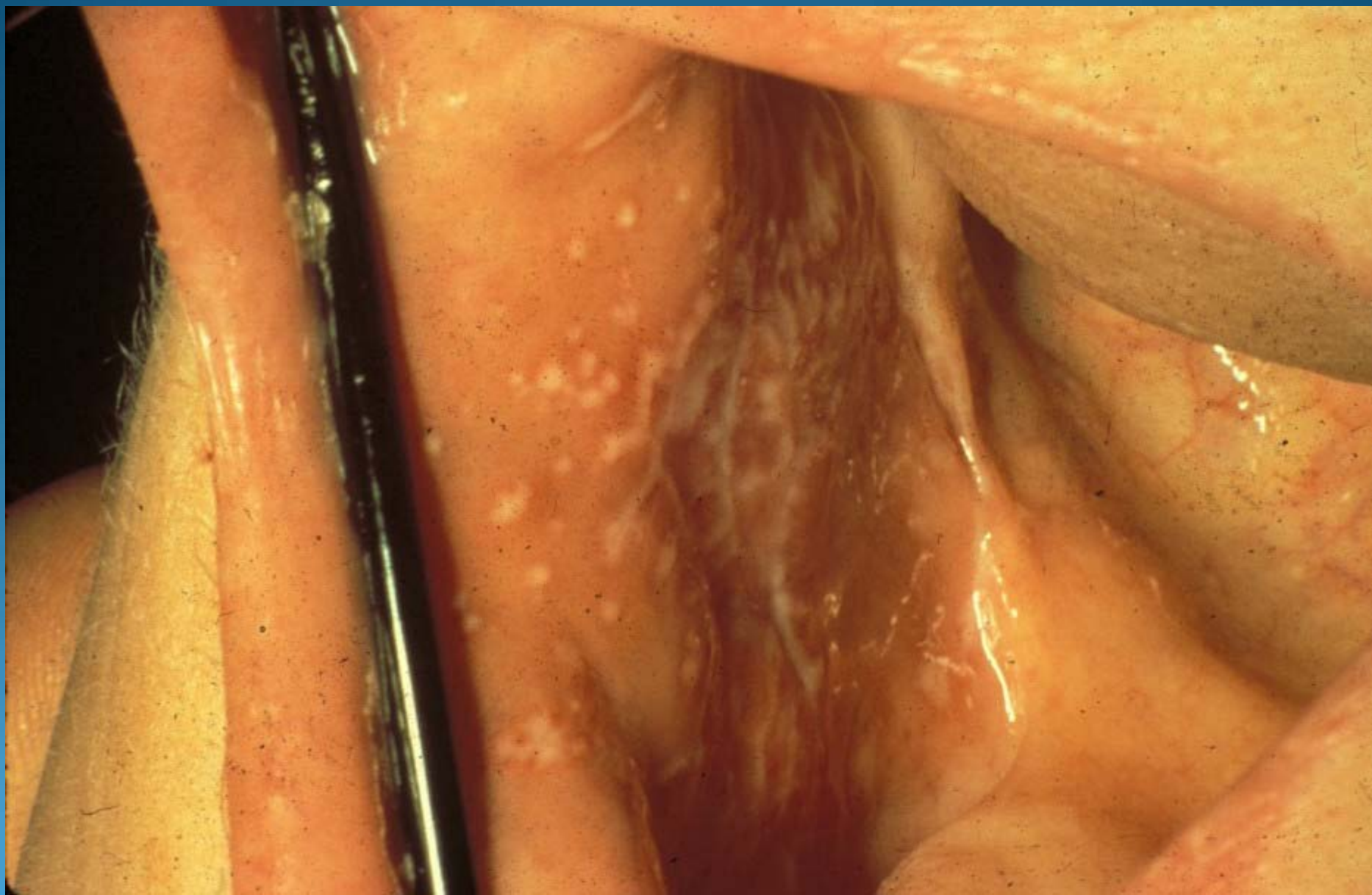- Some cases are drug induced
 - especially gold, thiazide diuretics and penicillamine
- Most cases are idiopathic

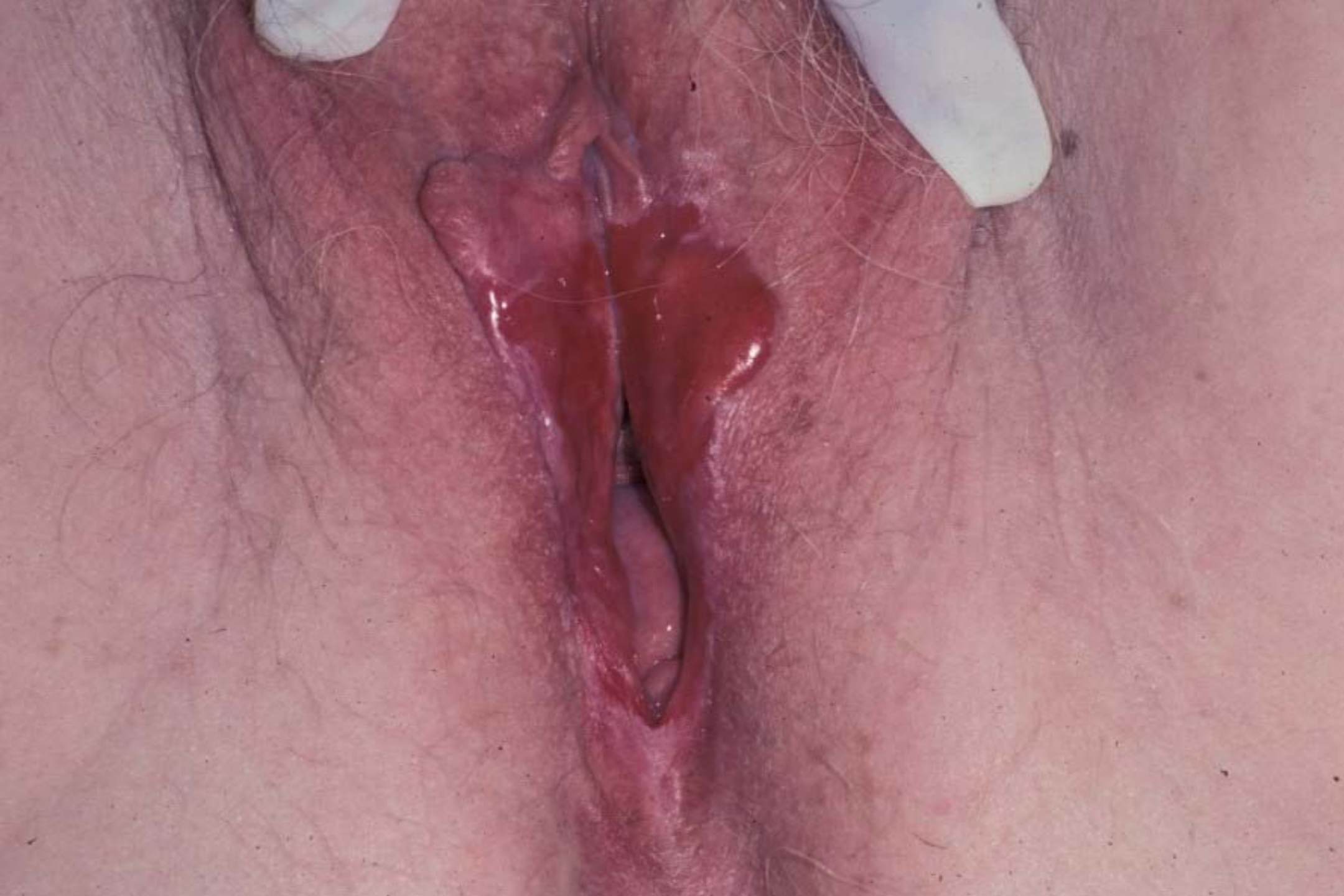The Five “P’s”

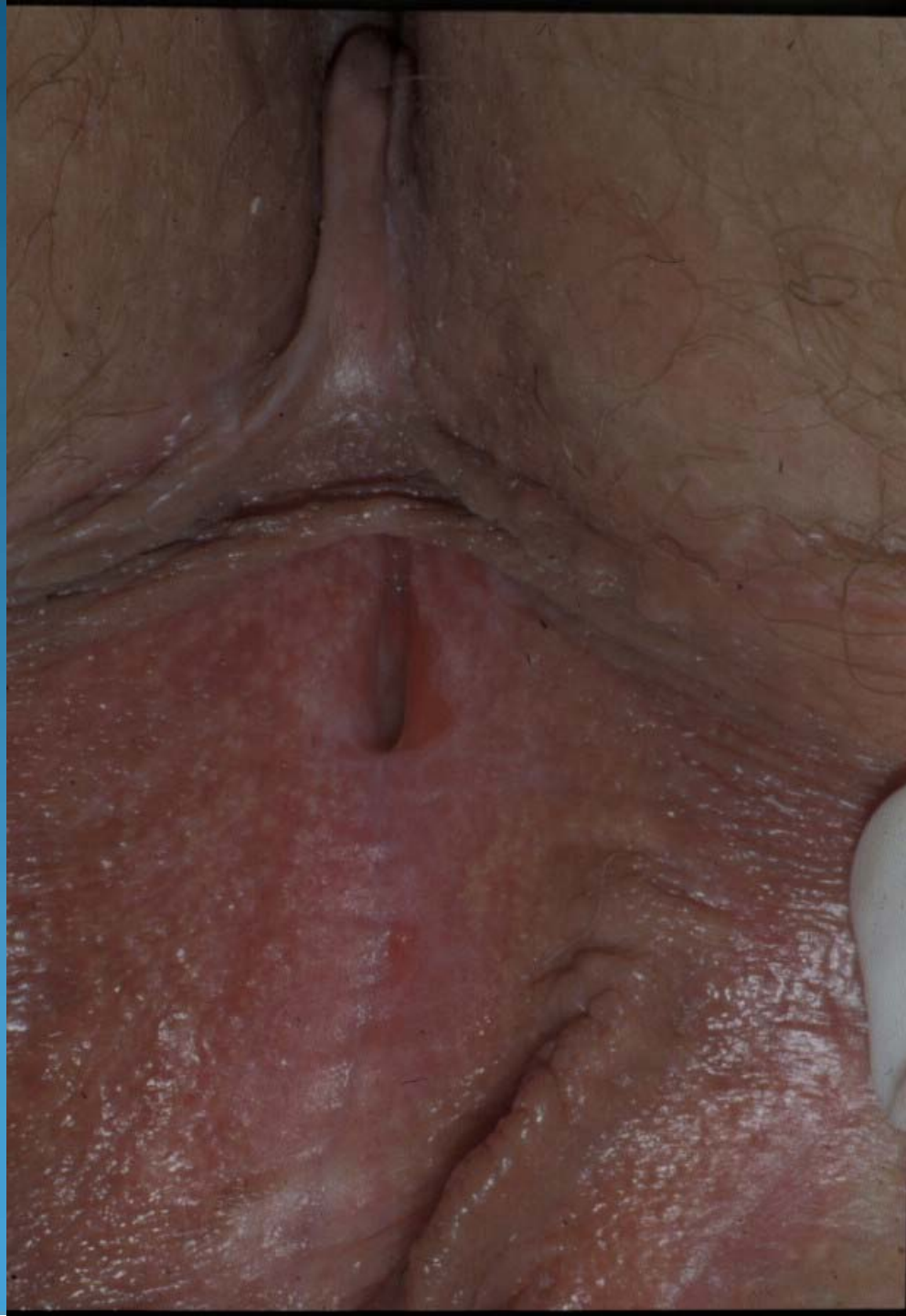- Pruritic
- Polygonal
- Purple
- Papules
- And Plaques











Treatment of Lichen Planus

- Biopsy if necessary to make the diagnosis
- Be sure to biopsy involved mucosa rather than erosions which could miss the pathology
- Do biopsy for immunofluorescence studies to rule out bullous diseases if rash is erosive

Treatment of Lichen Planus

- SITZ Baths
 - Cleansing
 - Soothing
 - Healing
 - Antipruritic

NDC 23317-910-16

white petrolatum

usp

topical lubricant
skin protectant

NET WT. 1 LB. (453.6g)

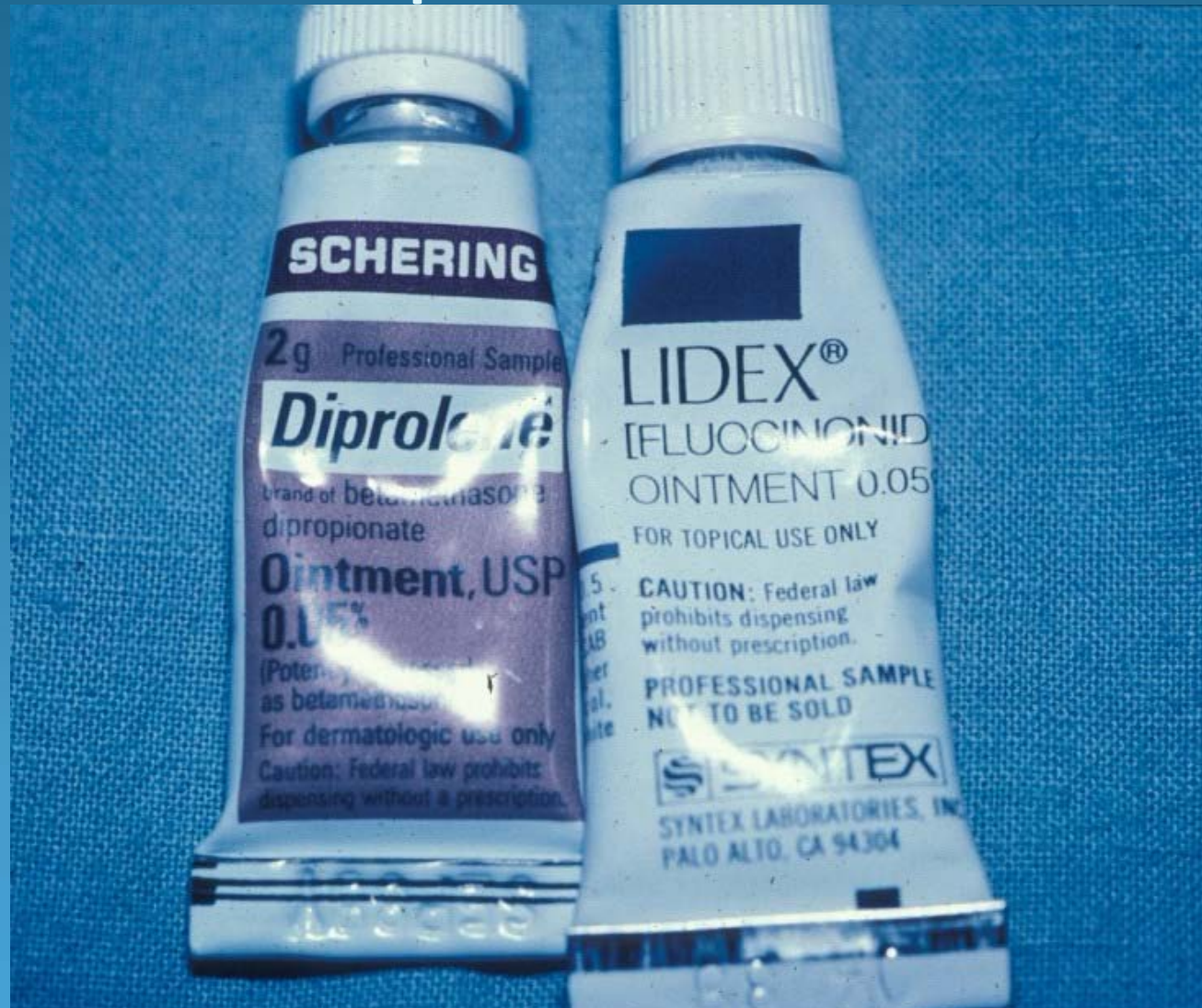Distr. by:

NMC LABORATORIES, INC.
GLENDALE, NY 11385

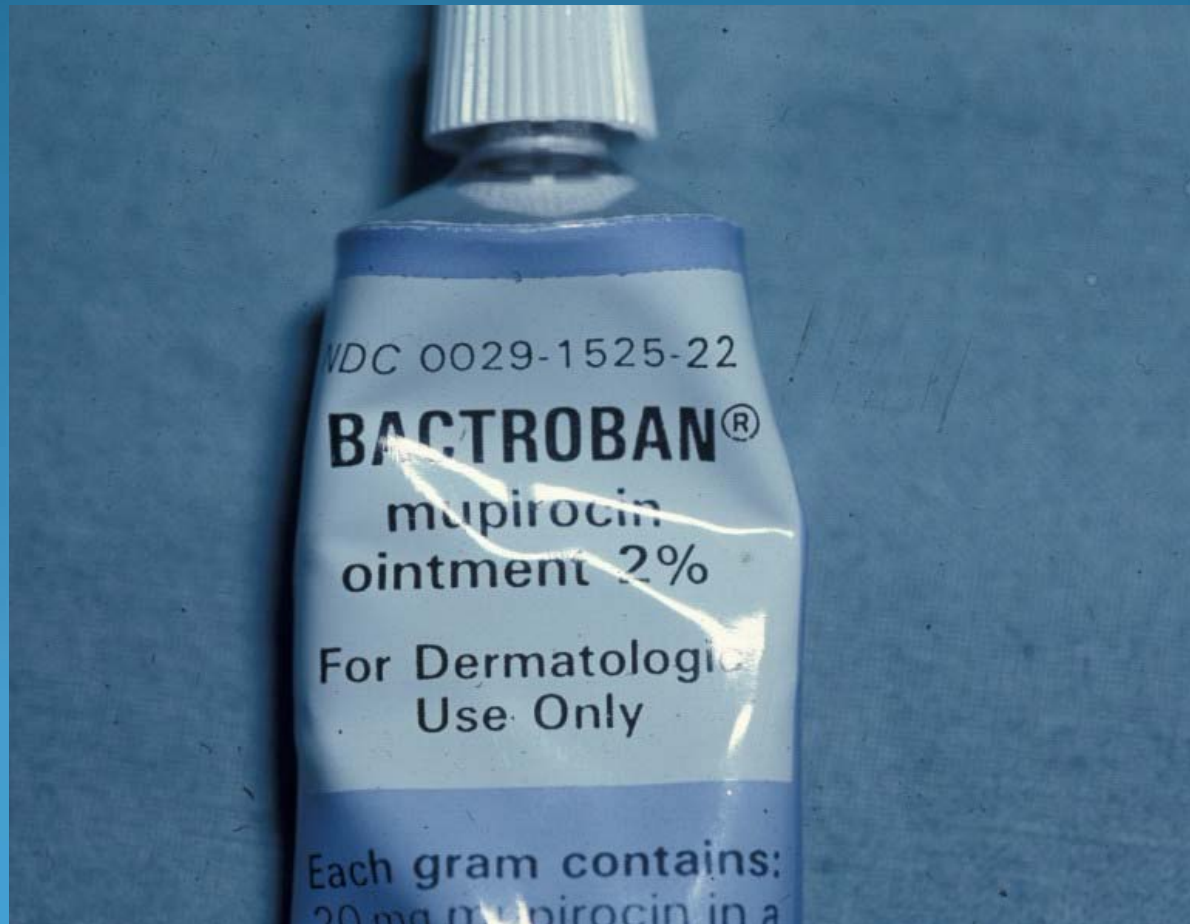8177-7250



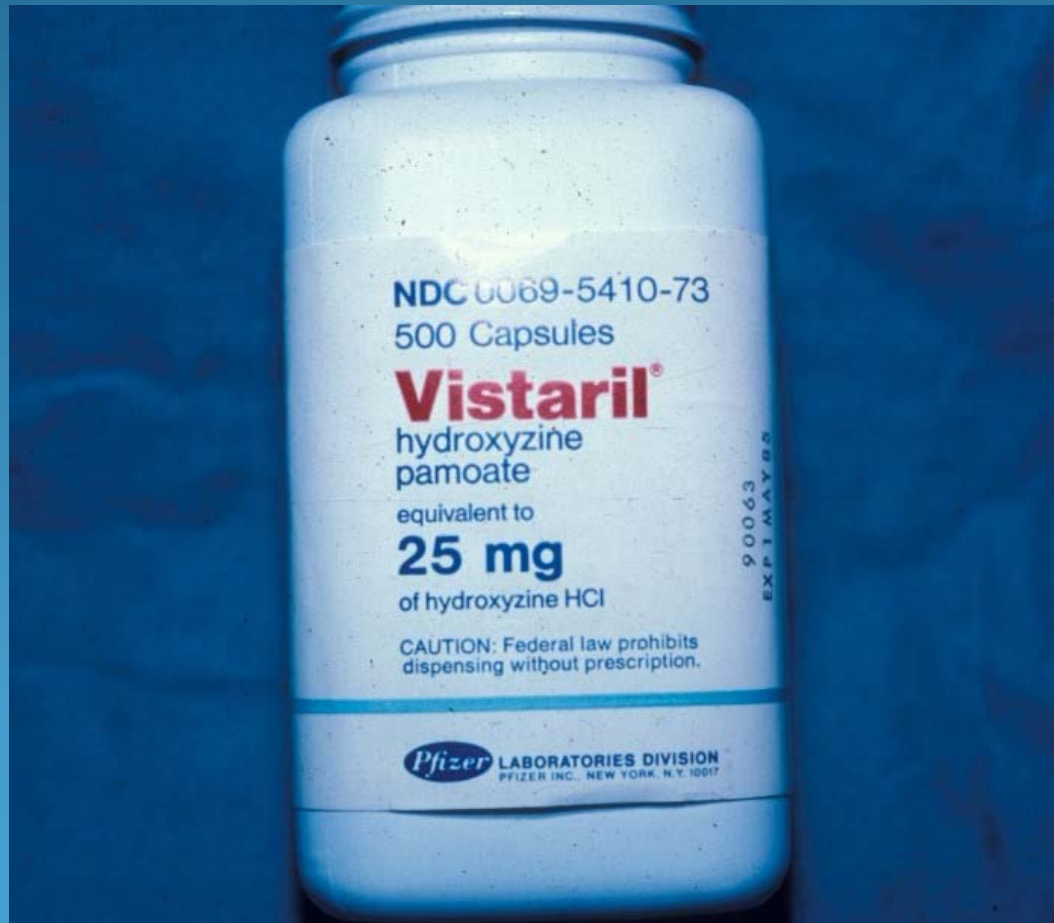Potent Topical Steroid Ointment



If erosions are present:



For itching:



Erosive Vaginal Lichen Planus

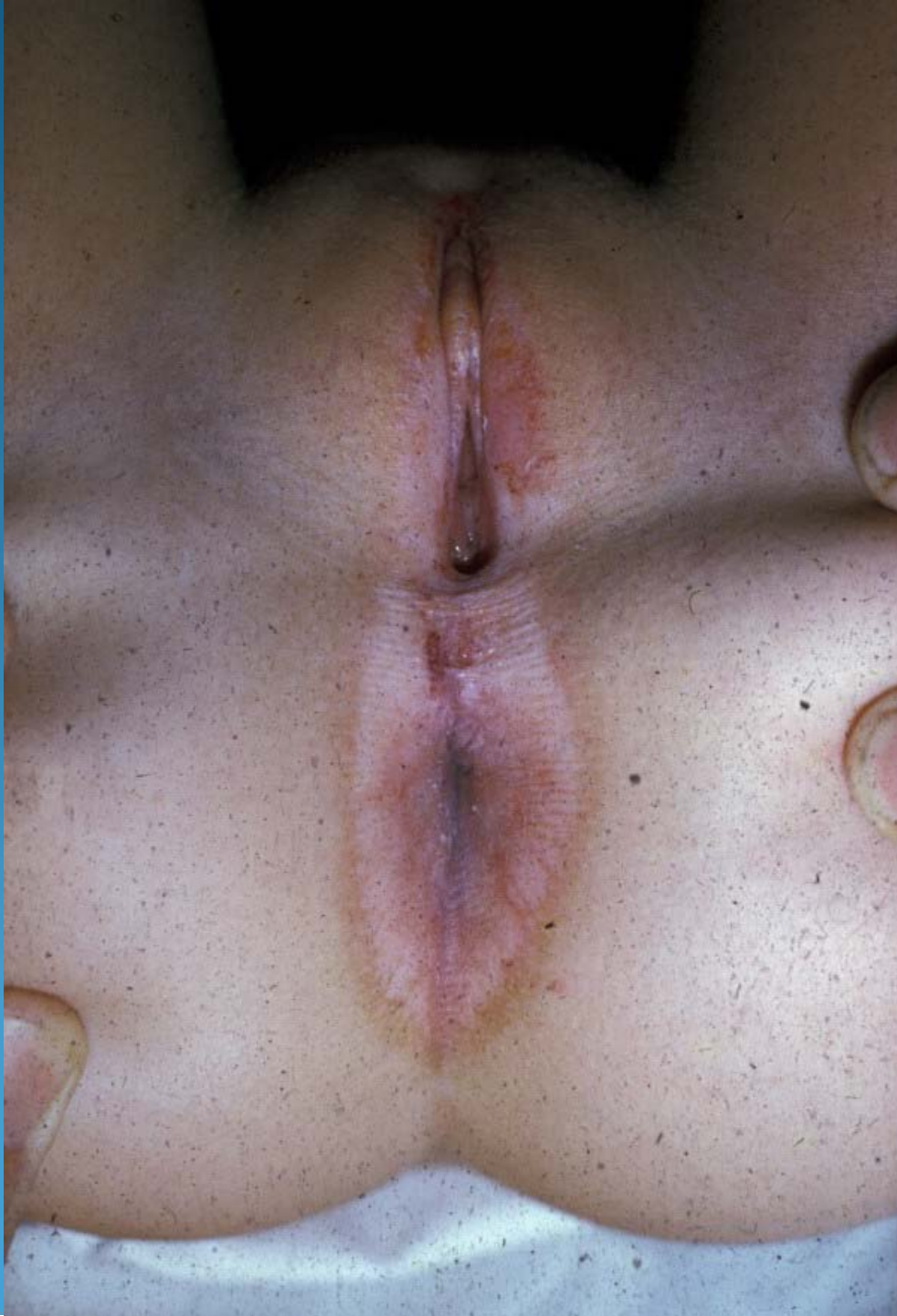- Some consider the same as “desquamative inflammatory vaginitis” (DIV)
- May require a burst of systemic steroids
- Intravaginal or oral Clindamycin
- Intravaginal hydrocortisone (proctofoam)
- Oral fluconazole 150 mg per week to prevent secondary yeast infections

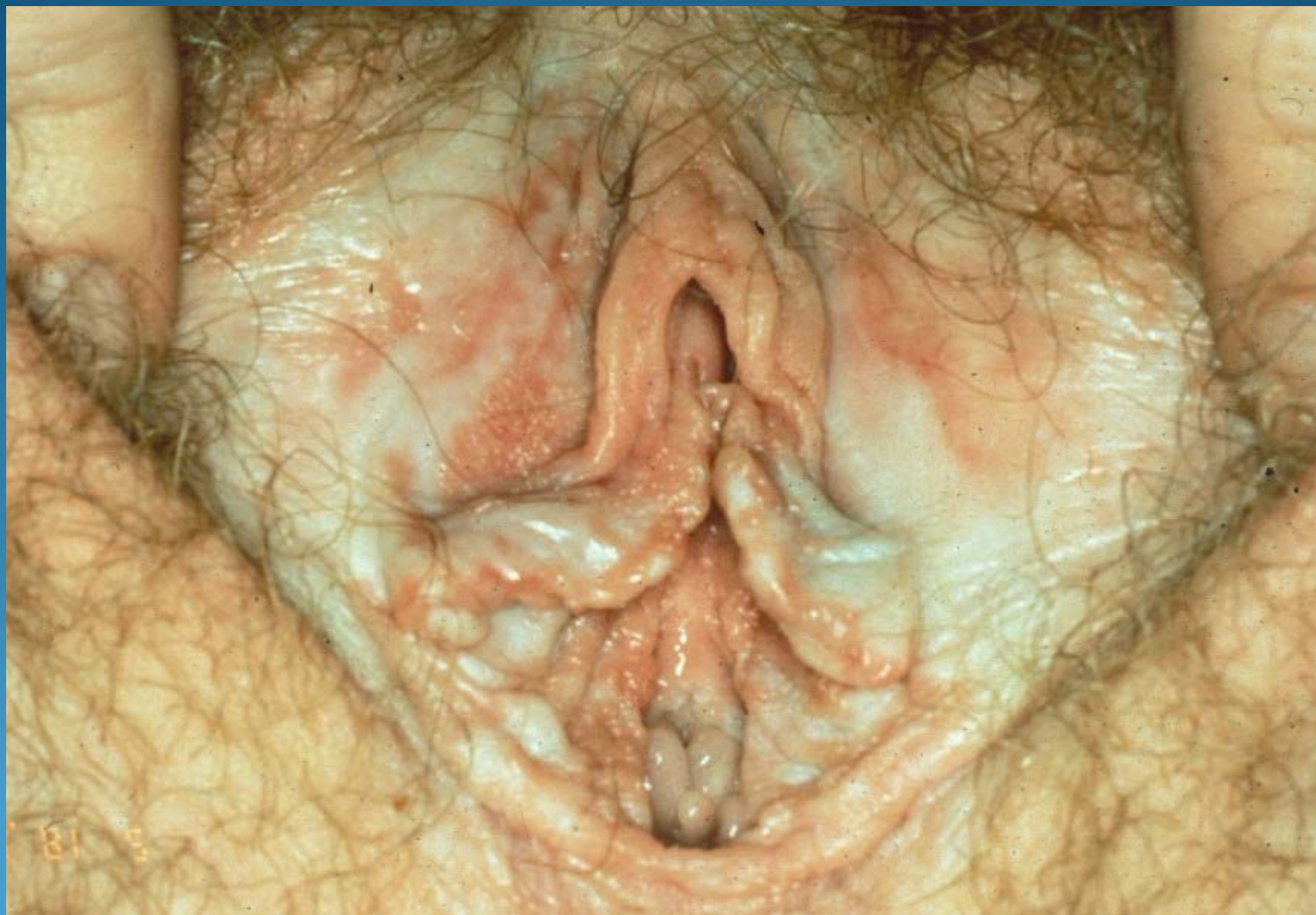Treatment of LP

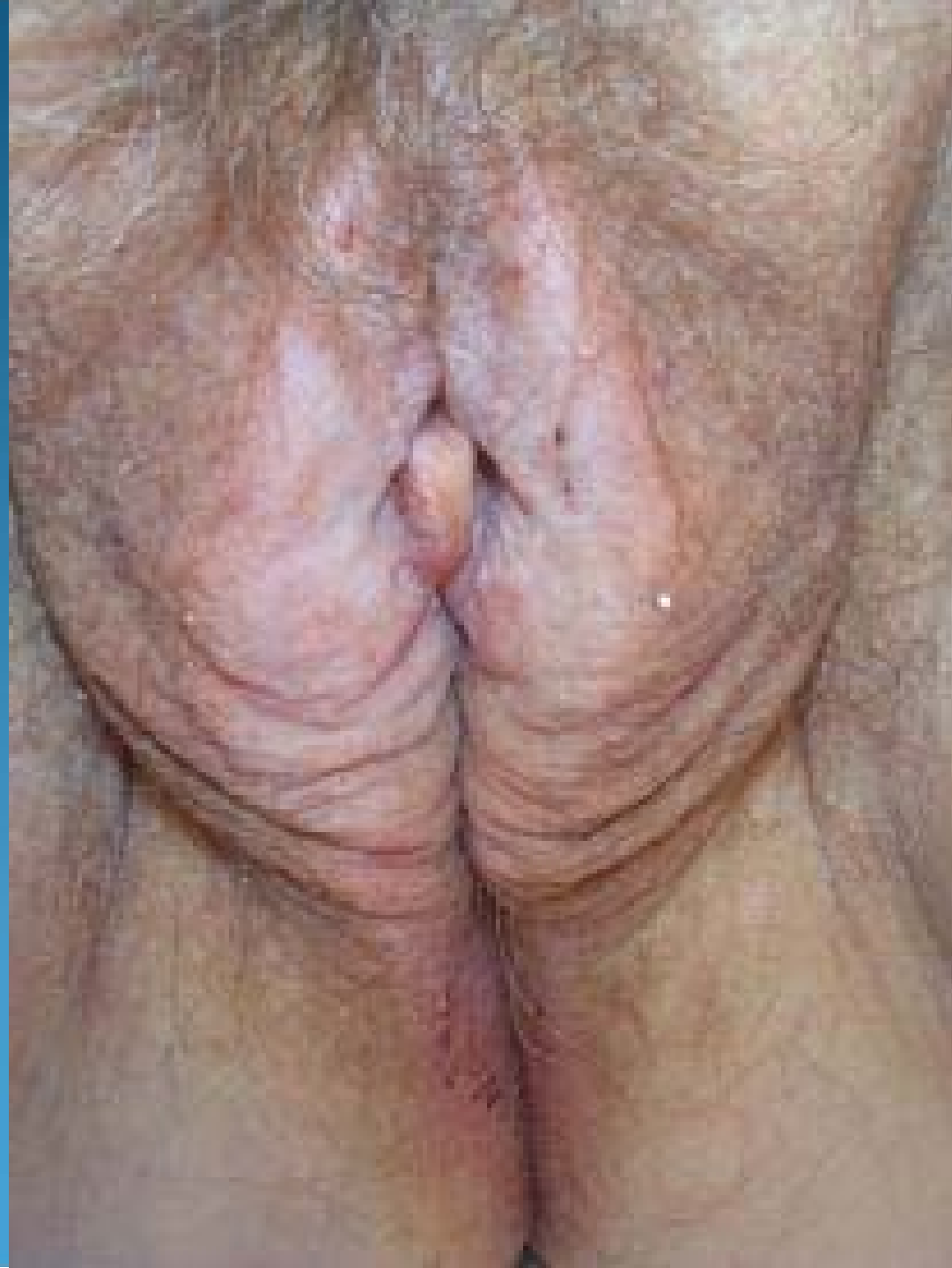- ?Protopic (tacrolimus) for erosive VAGINAL LP controversial because intravaginal Rx can cause significant blood levels
- Use of dilators may help avoid shrinking of vaginal opening

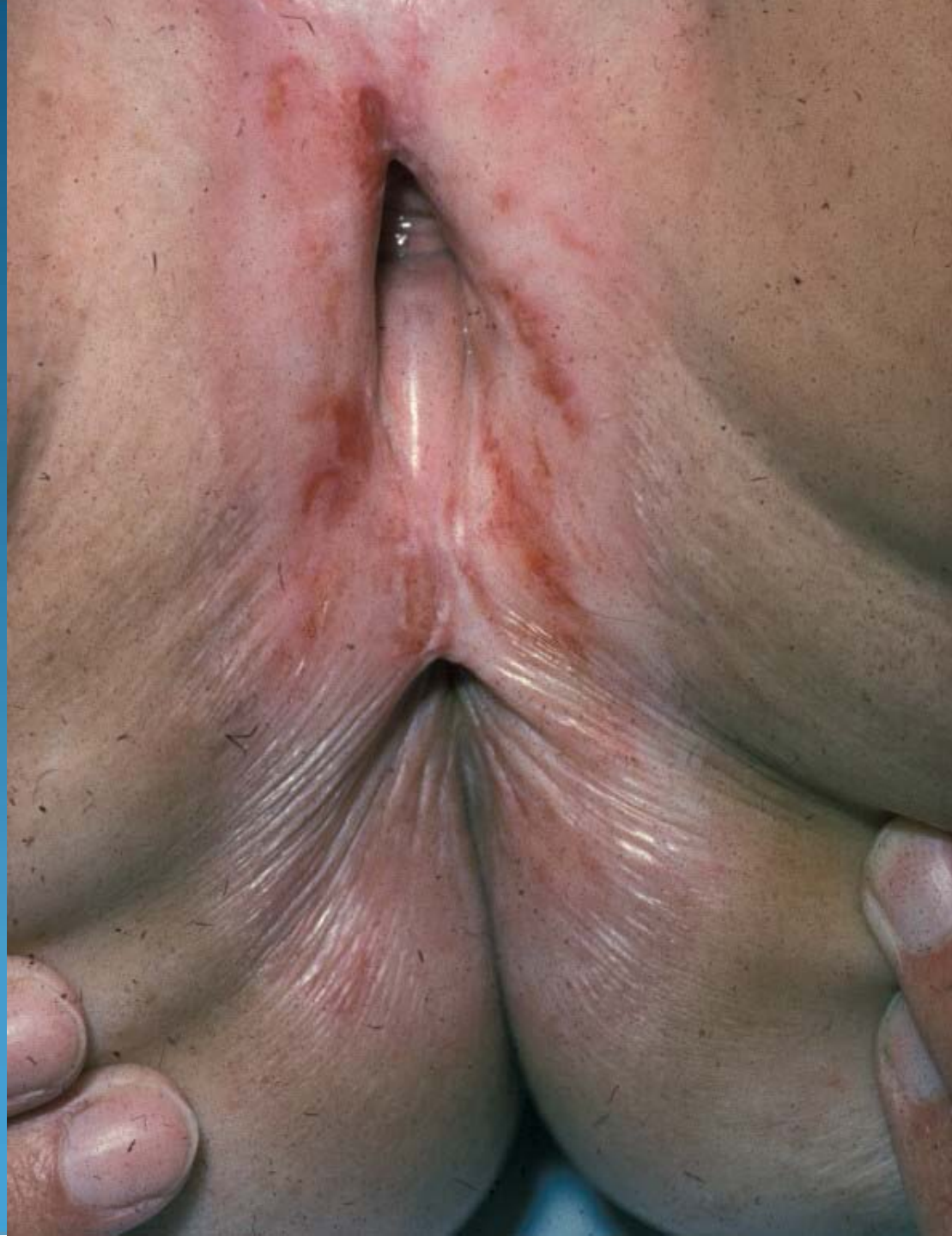Lichen Sclerosus

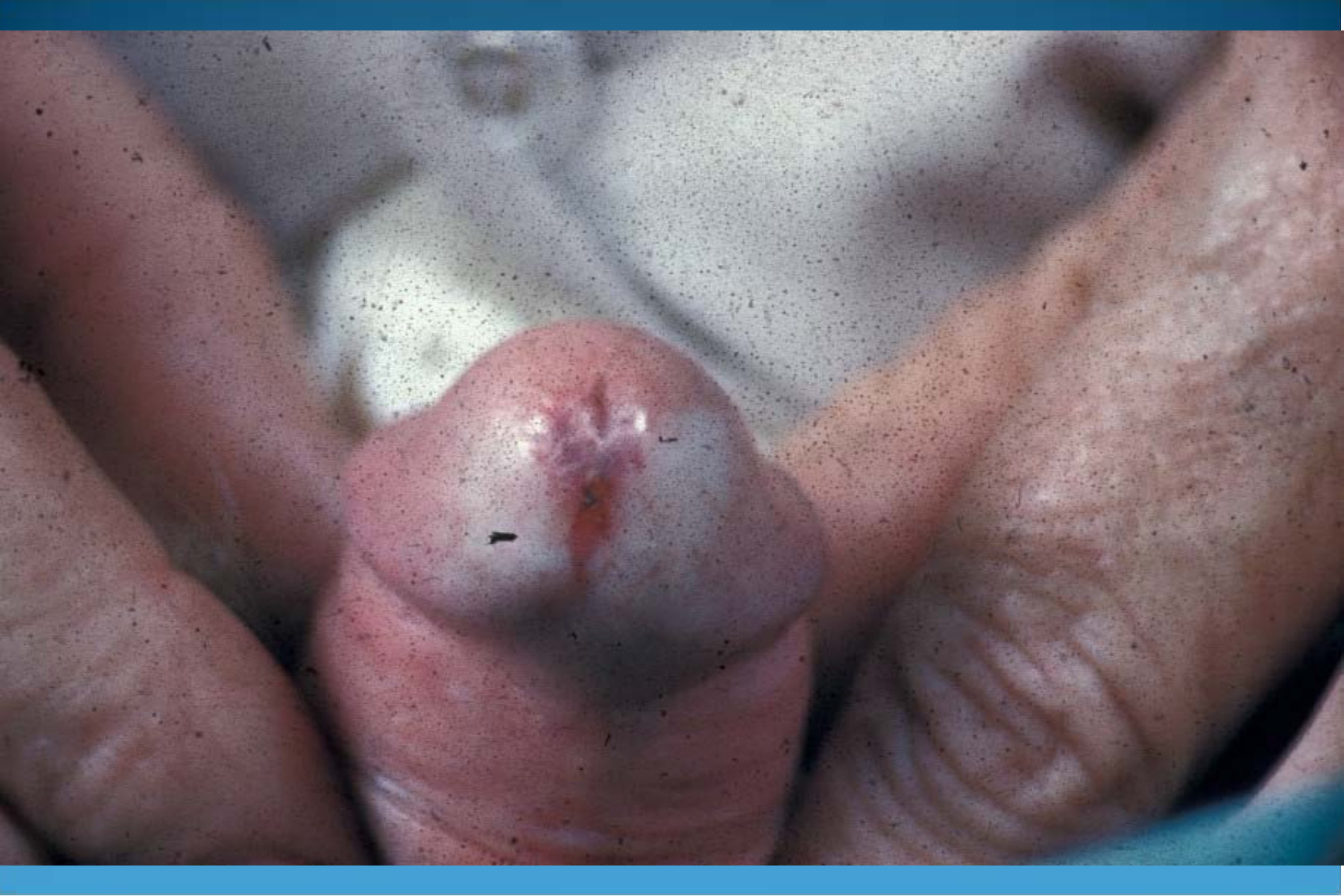- Most common in prepubertal girls and postmenopausal women
- Pruritic, white, wrinkled skin on vulva and perianal skin
- Early lesions may only show subtle erythema
- May be bullous, hemorrhagic or eroded

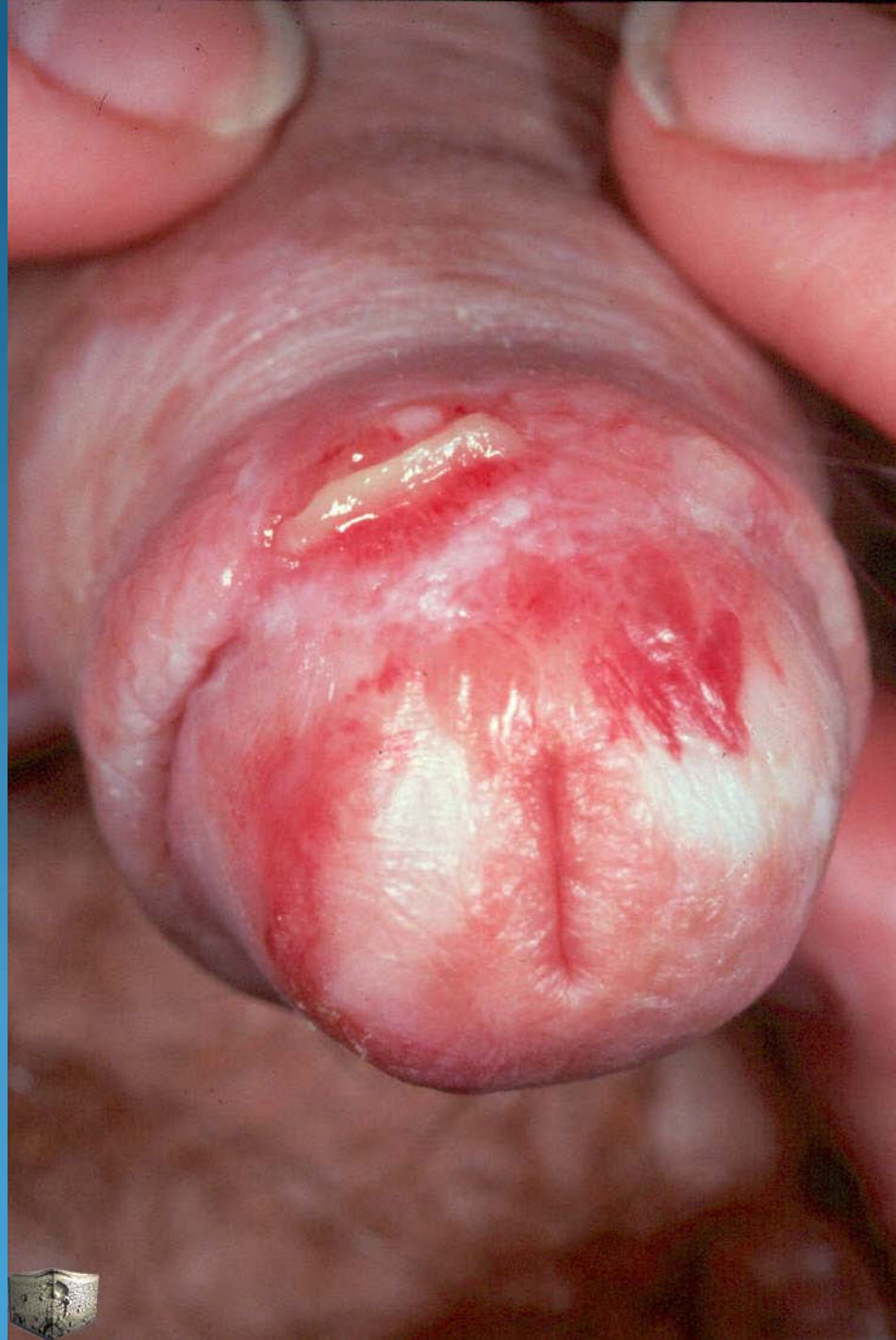


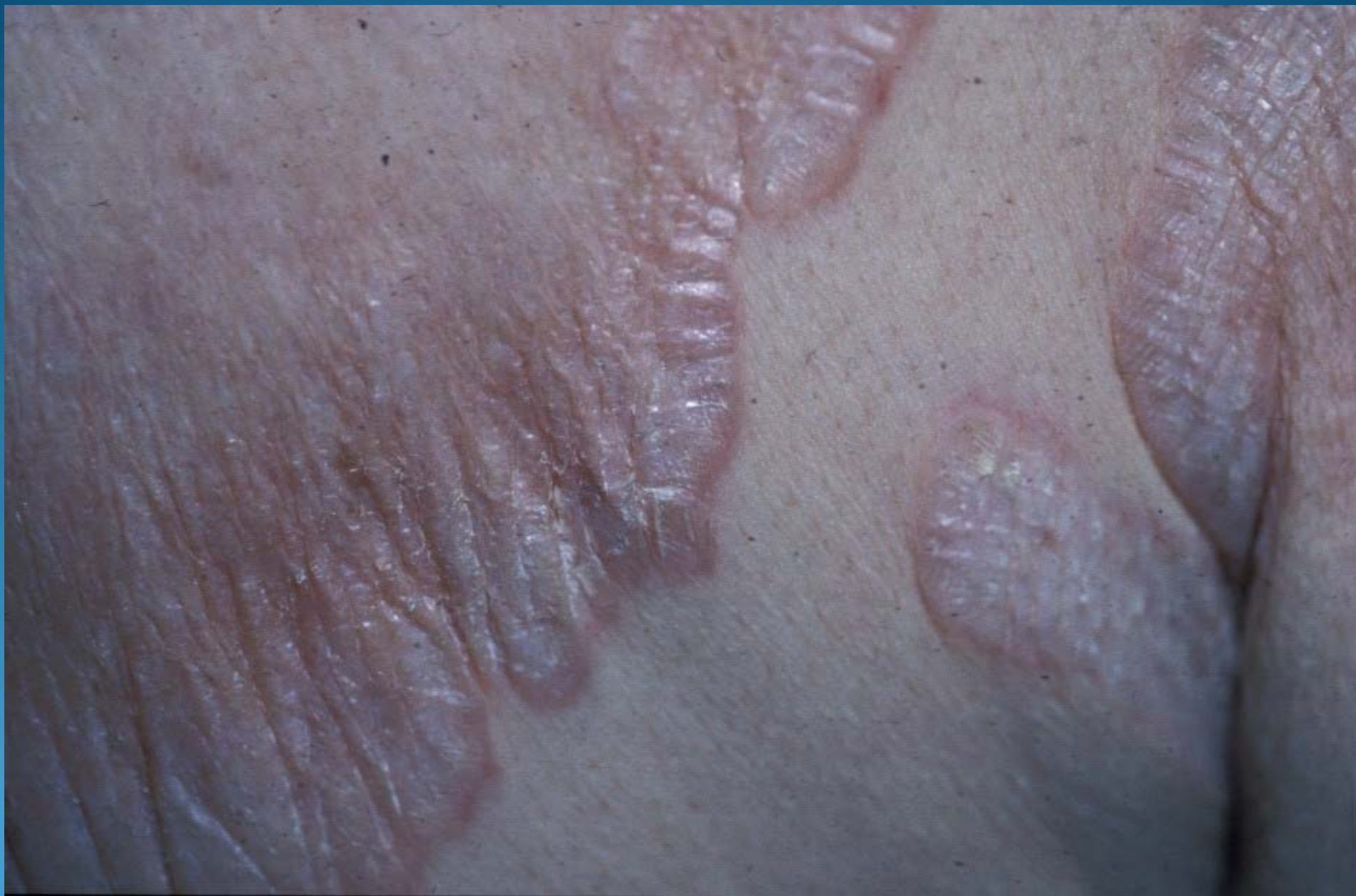


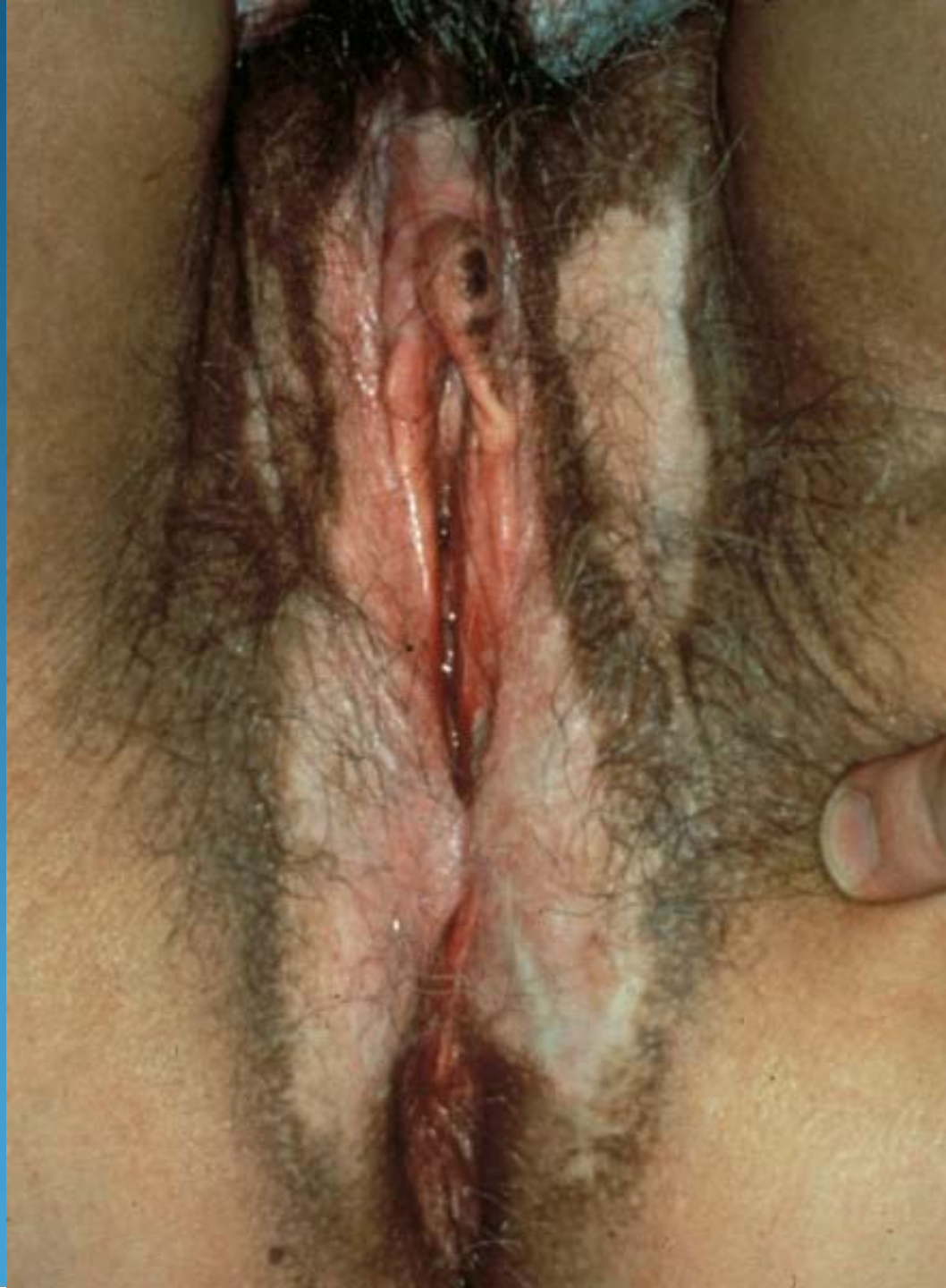





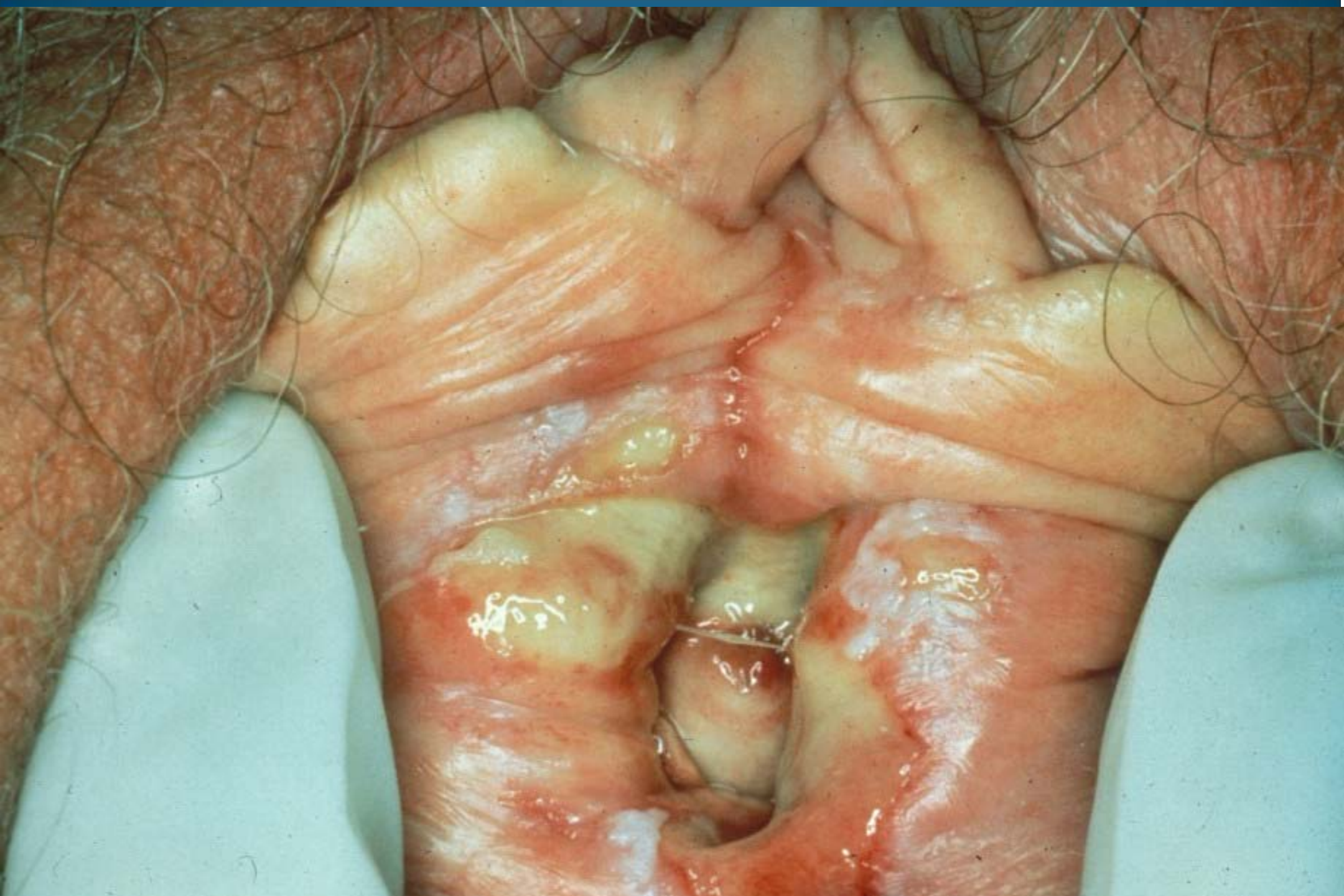


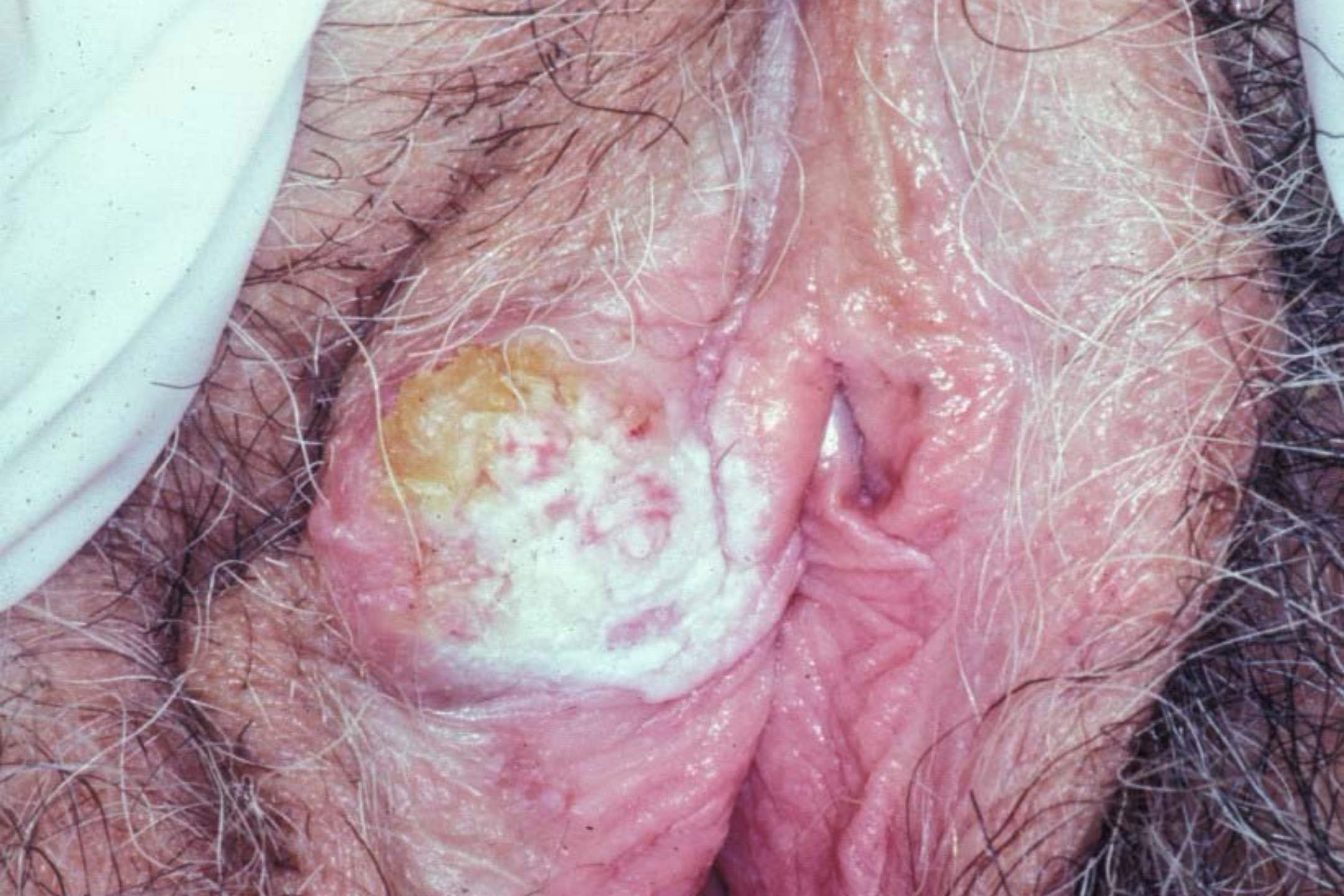






How do you make the diagnosis?

- Clinical observation
- Biopsy if necessary to confirm because the Rx for this condition is unique

Treatment of Lichen Sclerosus

- Sitz baths 2-3 times a day
- Apply petroleum jelly
- Apply mupirocin ointment to any fissures

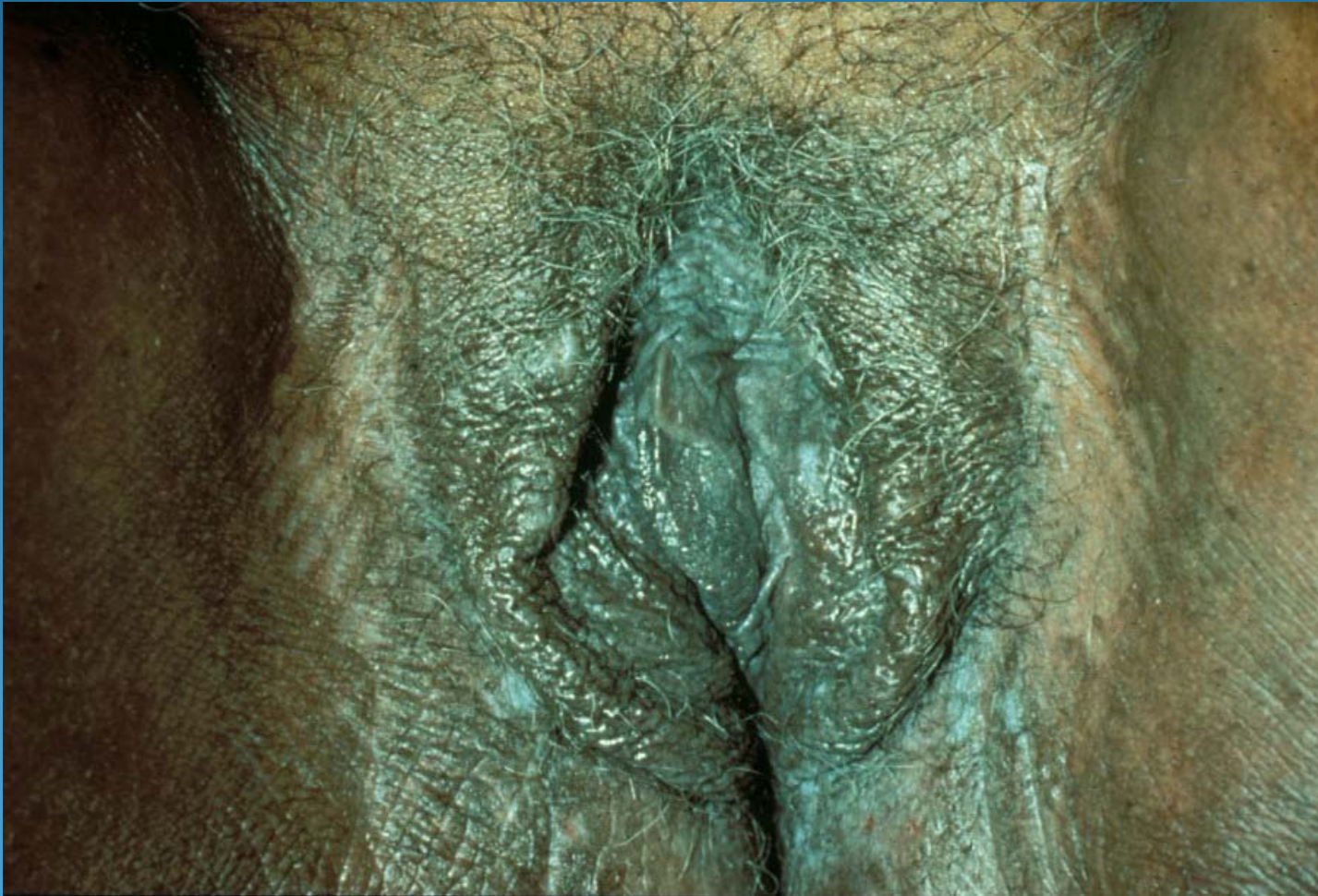Lichen Sclerosus Rx

- Testosterone is out
- Clobetasol propionate ointment (not cream) is in
 - Nightly application for 3-6 weeks
 - Gradually taper to once a week depending on response
 - Long term Rx?

Lichen Sclerosus Rx

- Dilators
- Surgery
- Follow

Lichen Simplex Chronicus



LSC-Look for the underlying cause

- Atopic dermatitis
- Seborrheic dermatitis
- Contact dermatitis
- Pubic lice
- Scabies
- ETCETERA!

SCHERING

30 ml NDC-0085-0182-04

Lotrimin[®]
brand of clotrimazole
Solution, USP
1%

For dermatologic use only
Not for ophthalmic use

Caution: Federal law prohibits
dispensing without prescription.

NDC 0039-0009-30



Loprox[®] CREAM 1% 30
(ciclopirox olamine)*

For topical use only.

Caution: Federal law prohibits dispensing without prescription.
Store at controlled room temperature (59°-86°F).

NDC 0062-5434-01

Monistat-Derm[®] CREAM
TRADEMARK
(miconazole nitrate 2%)

Contains miconazole nitrate 2%, pegoxol 7-
stearate, peglicol 5 oleate, mineral oil, benzoic acid,
butylated hydroxyanisole, and purified water.

For Topical Use Only

Caution: Federal law prohibits dispensing
without prescription.

Dosage: See package insert.

Store below 86°F.

Warning: Keep out of reach of children.

DERMATOLOGICAL DIVISION
ORTHO PHARMACEUTICAL CORPORATION
Raritan, New Jersey 08869

NET WT. 1.1

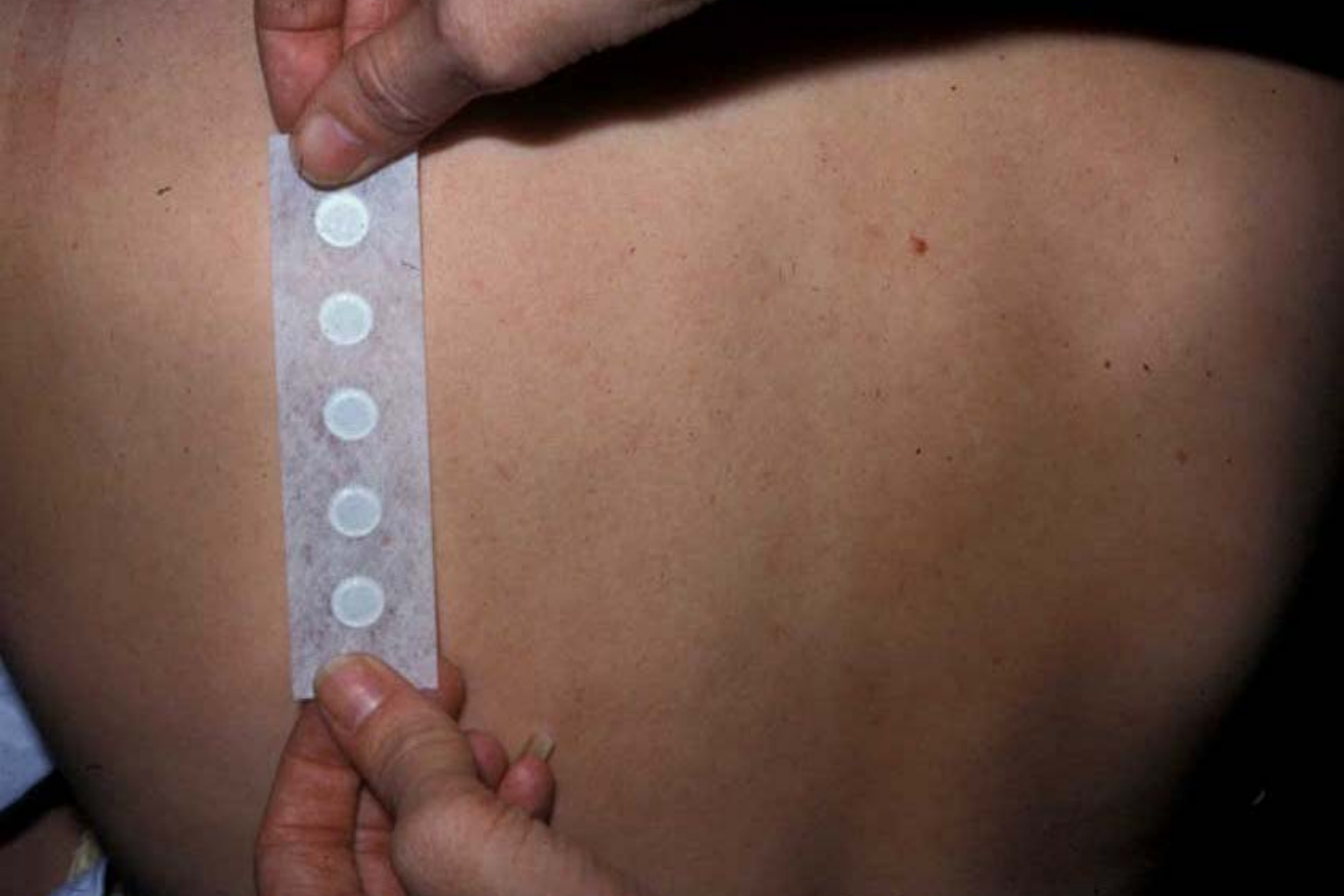


Mycelex[®] 1%
(clotrimazole) cream 30g

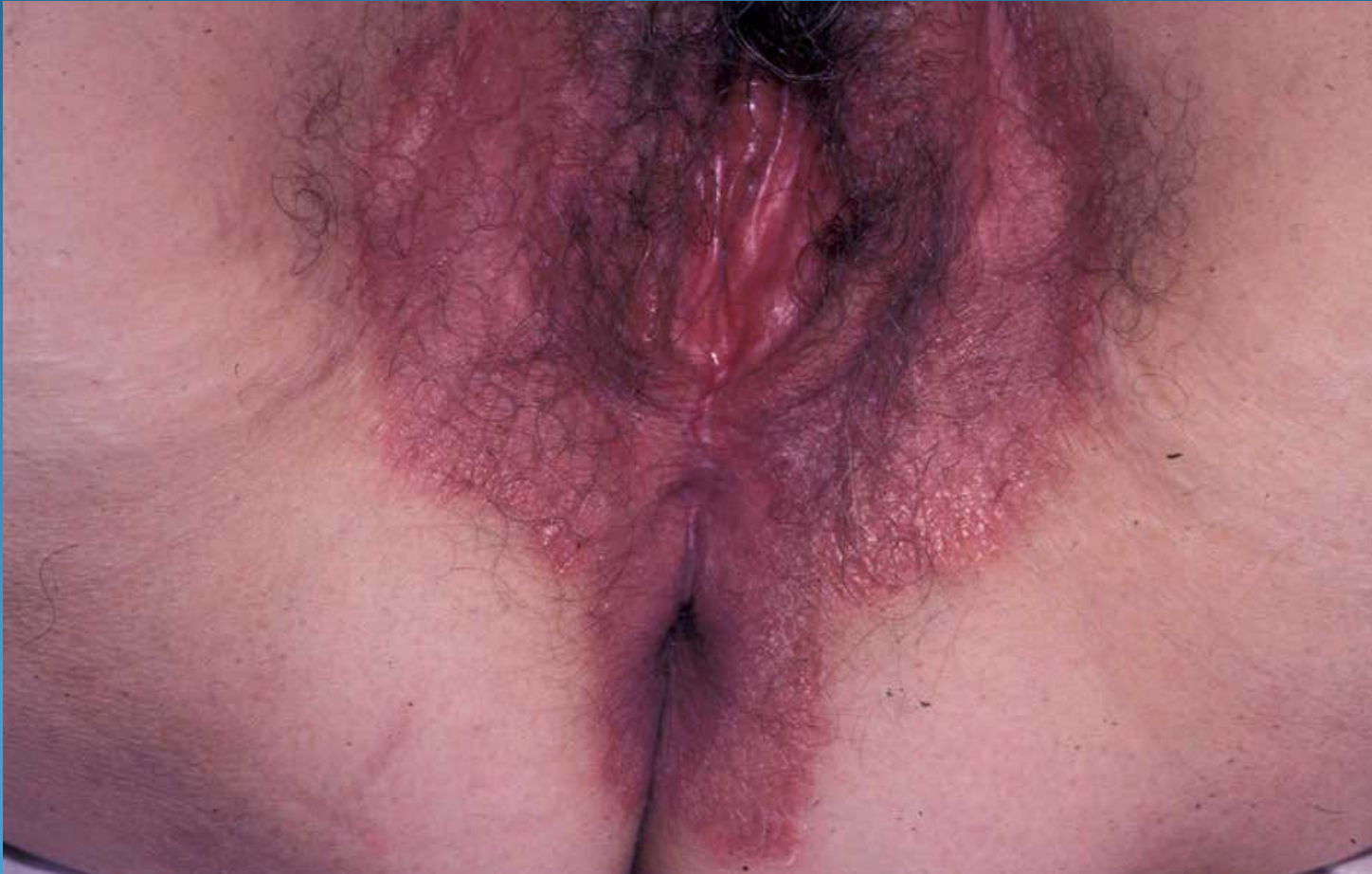NDC-0026-3091-
309120

For dermatologic use only

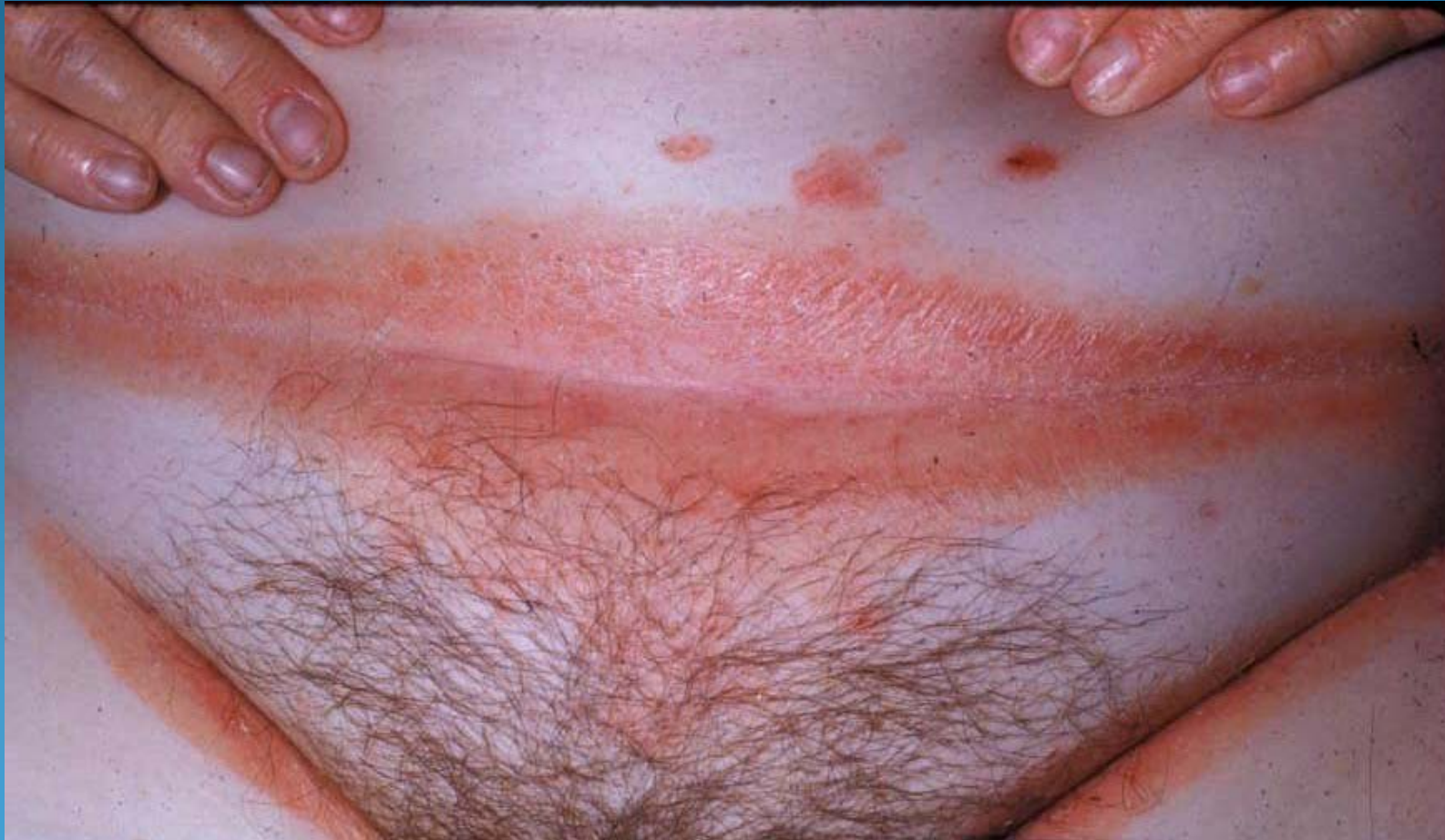Caution: Federal (USA) law prohibits dispensing without prescription.



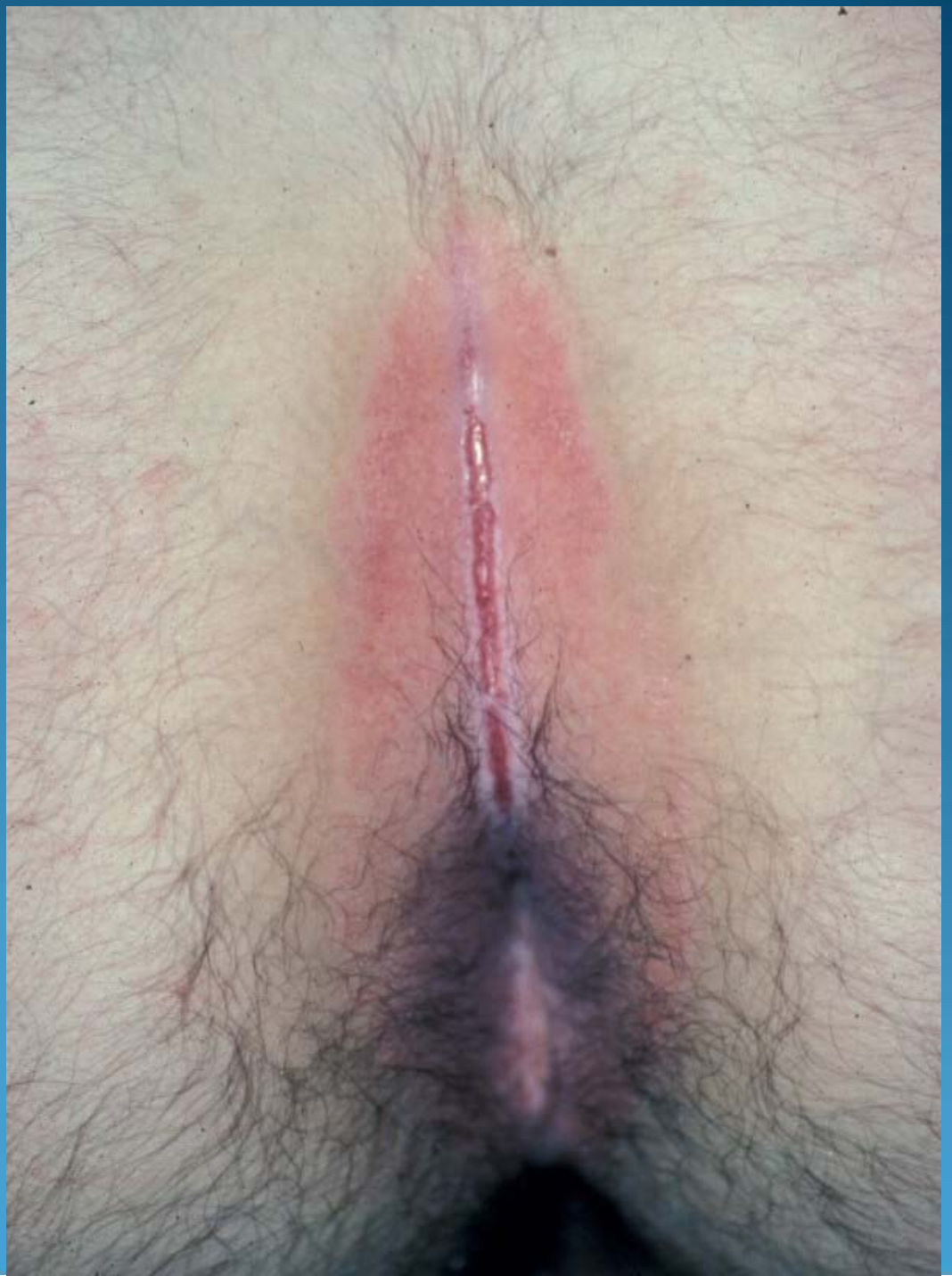Psoriasis

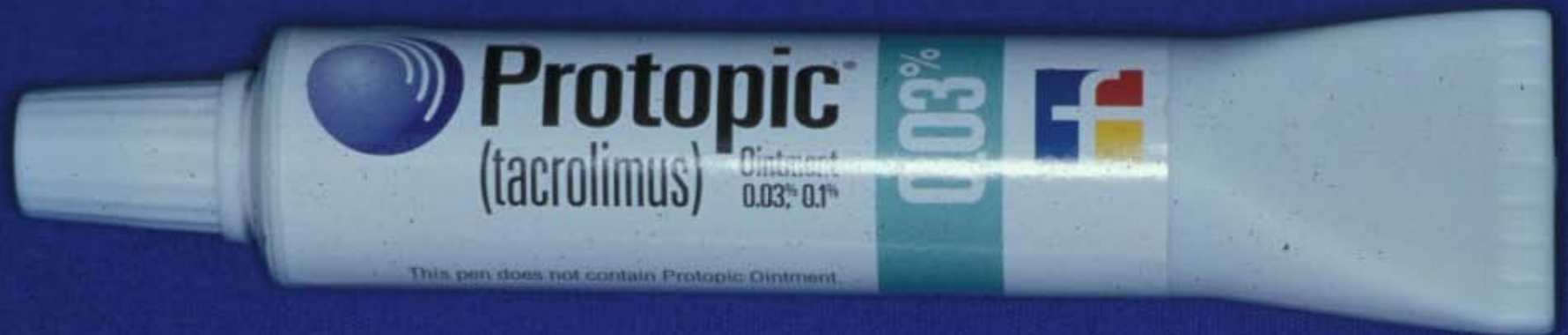

Seb Derm



Gluteal Cleft fissure

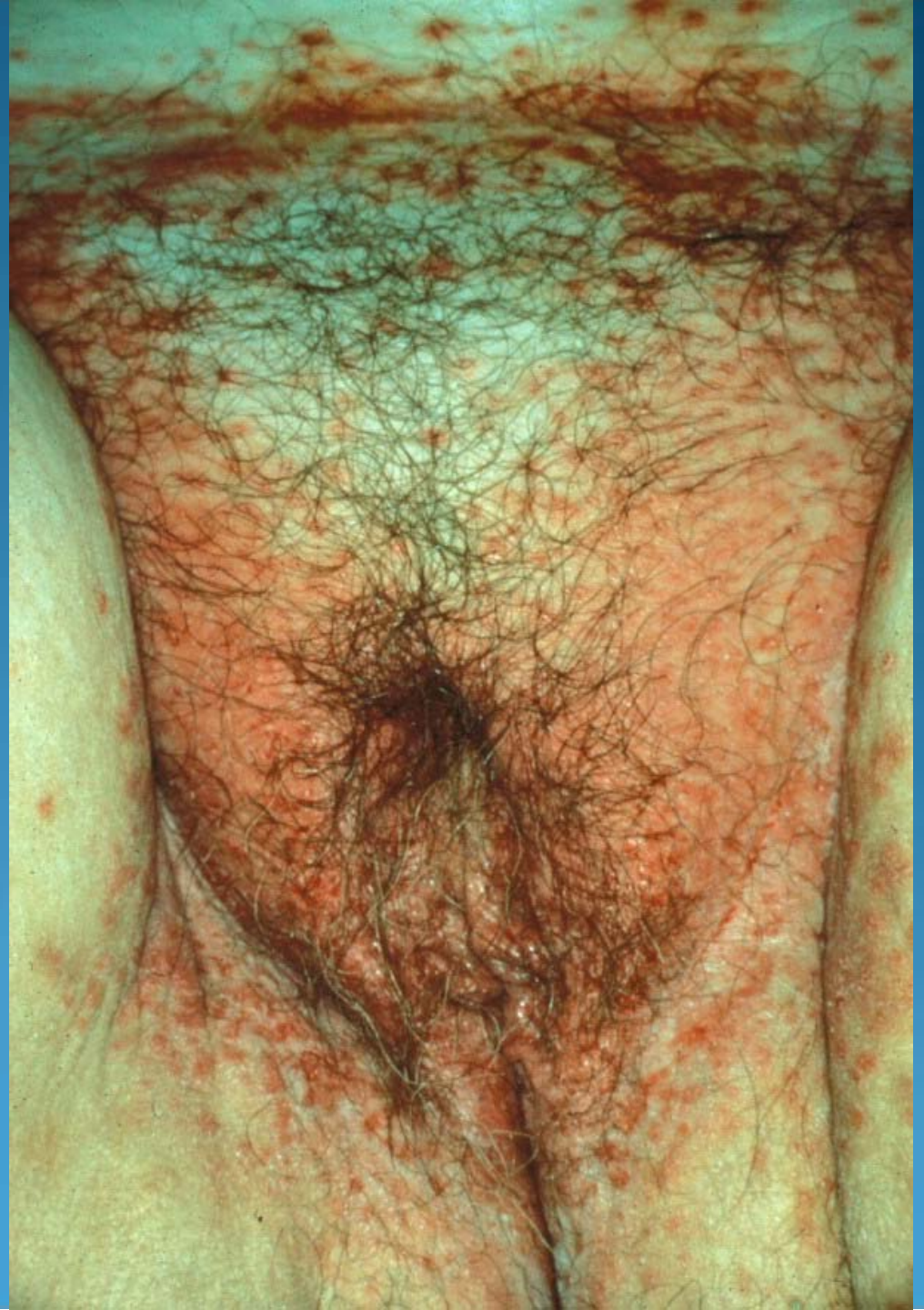


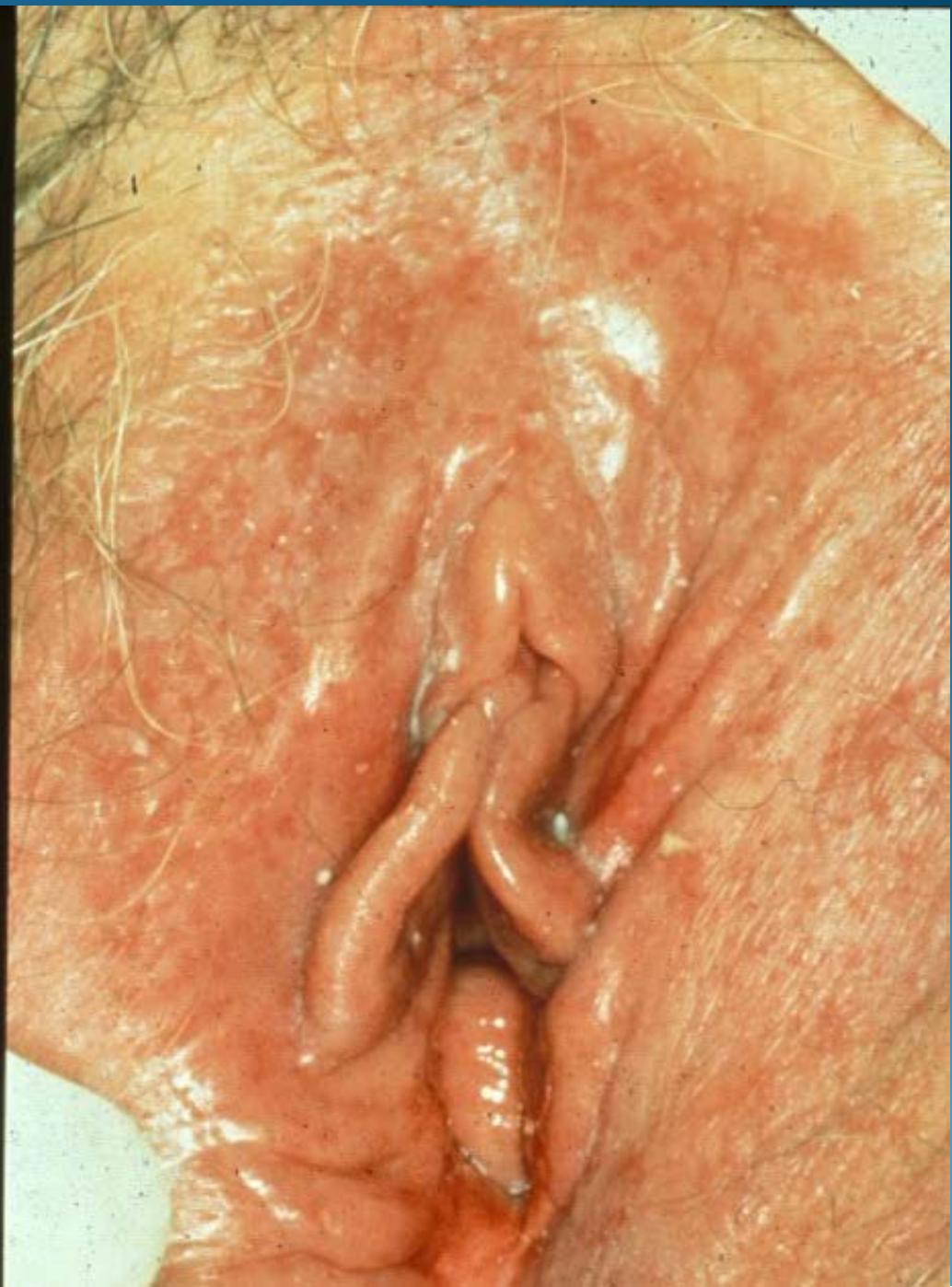
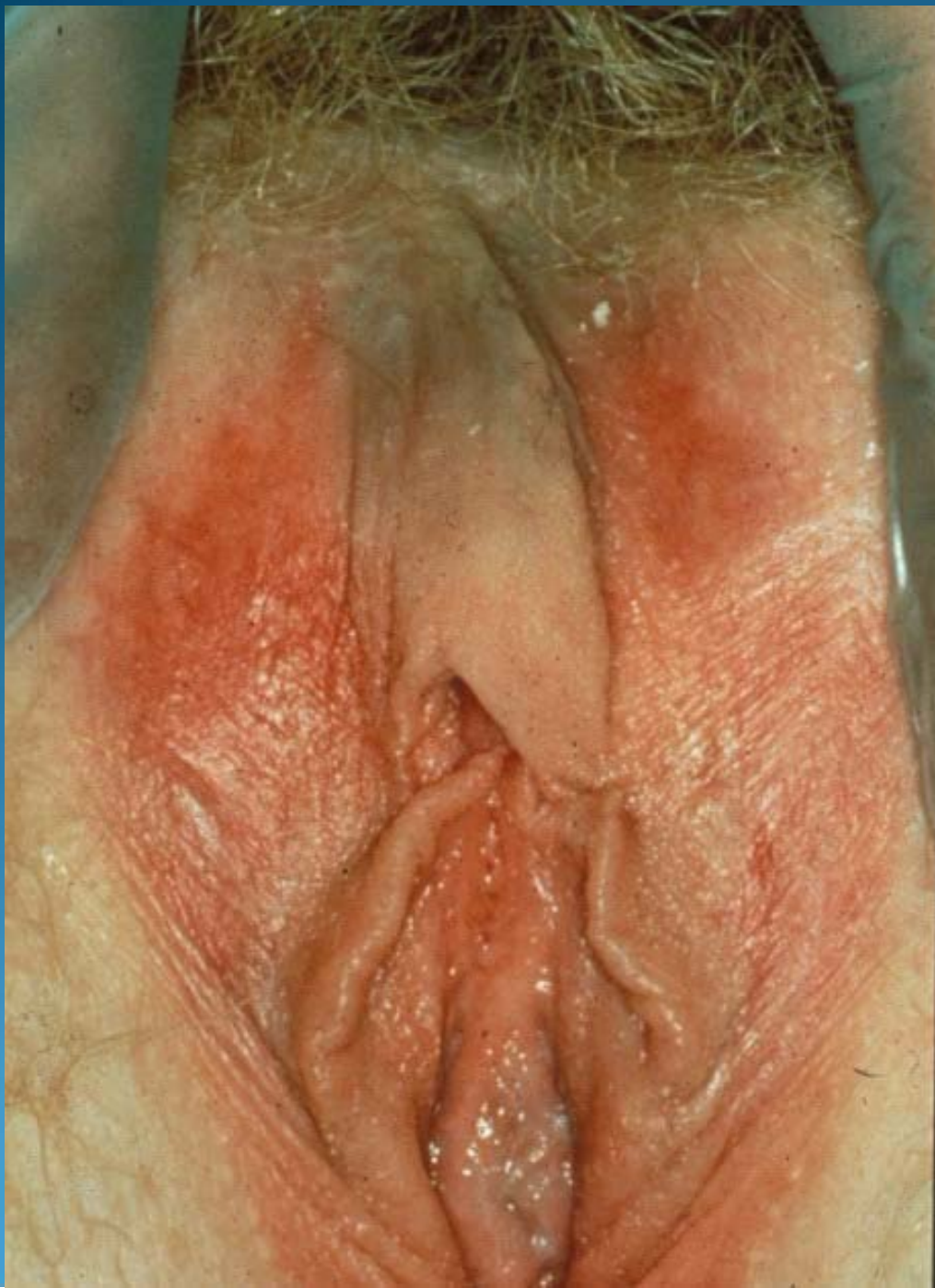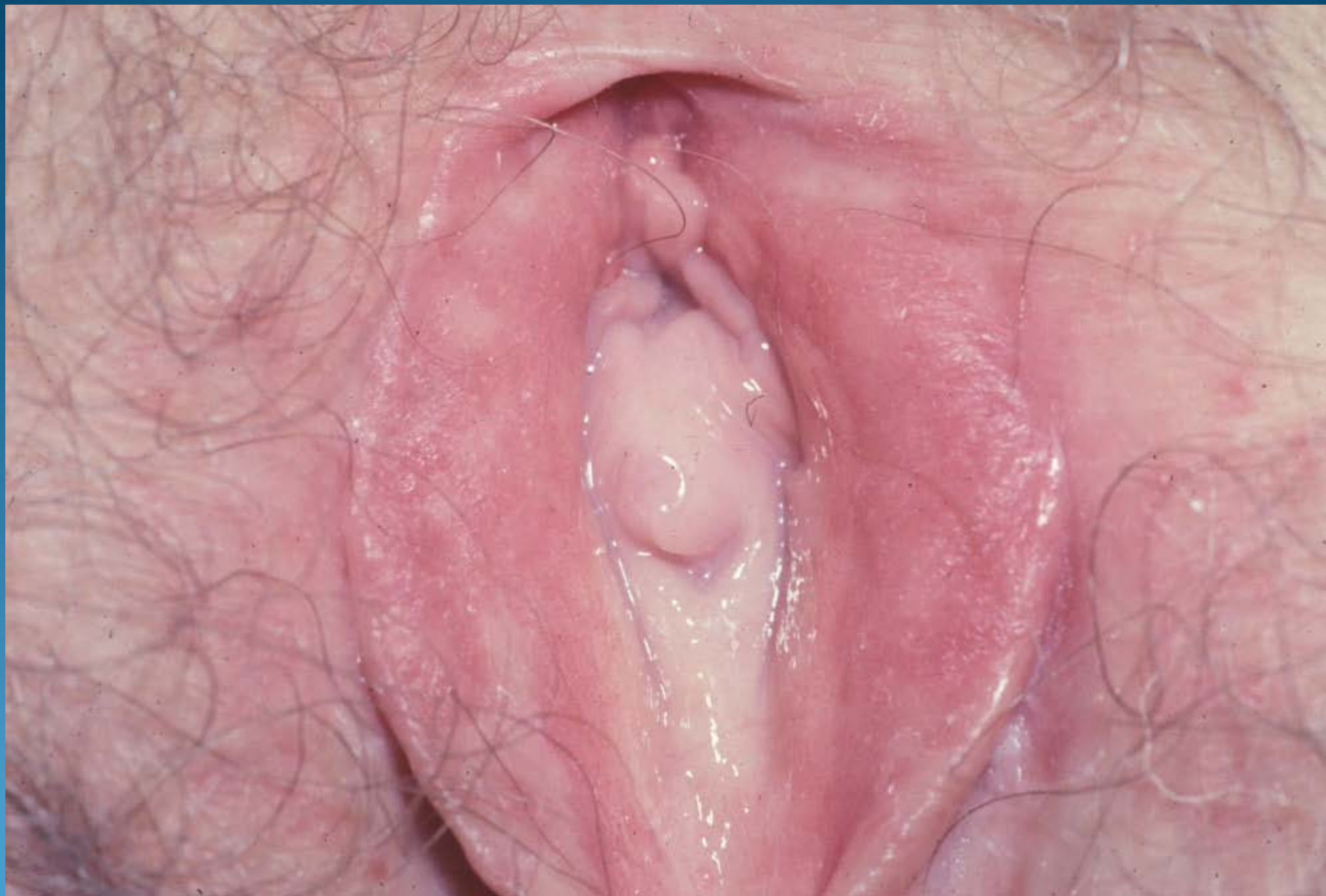Posterior Fourchette Fissure Treatment

- Sitz baths with bath oil
- Topical mupiricin twice a day until healed
- Oral or topical anticandidal therapy
- Avoid trauma and contactants
- ?Surgery

Candida







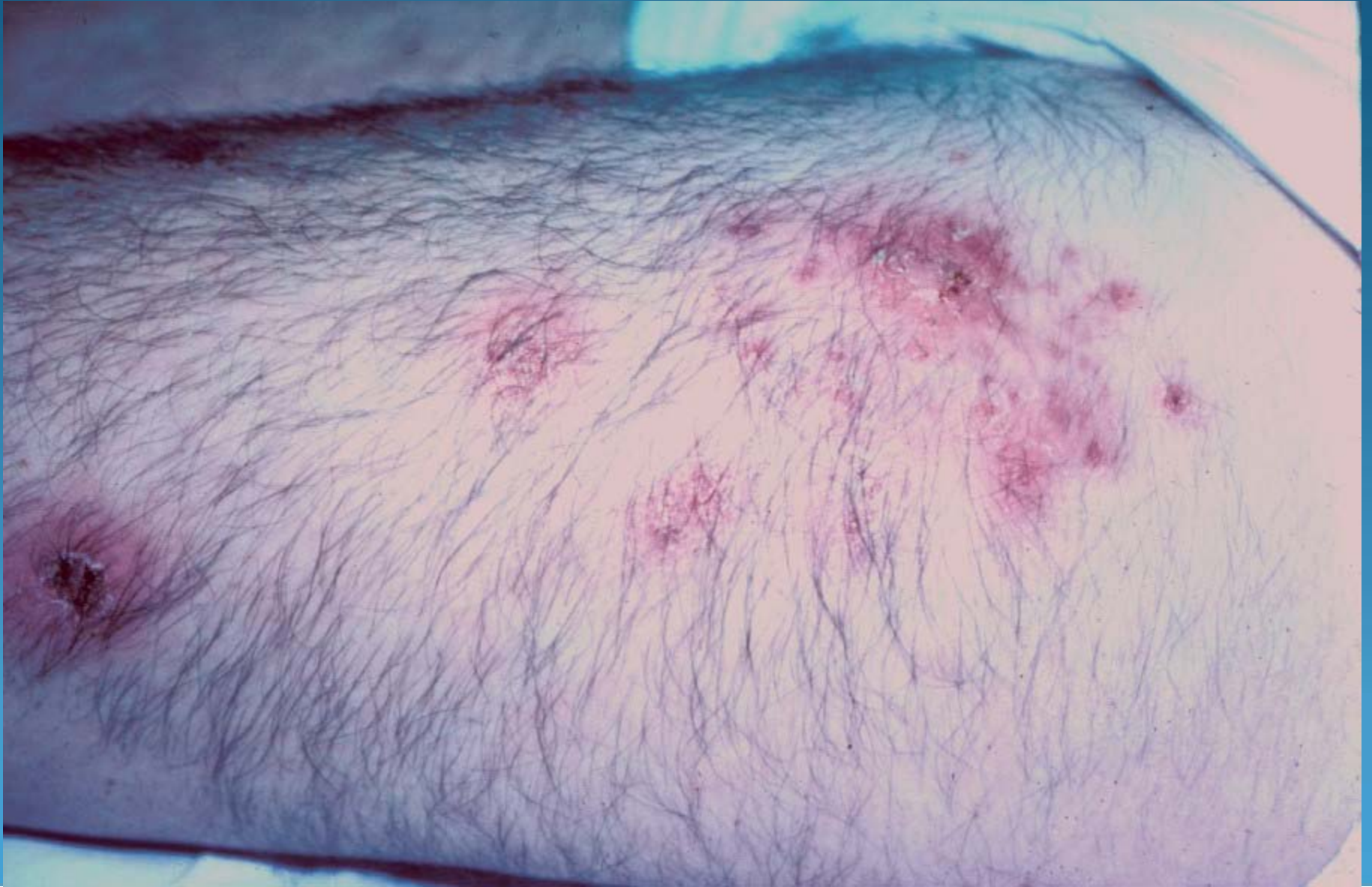GREER'S GOO

- 1% Hydrocortisone (powder)
- Nystatin Powder 1,000,000 Units
- Zinc Oxide Ointment qs ad 1 oz.

DON'T USE LOTRISONE

- Potent topical steroid may cause atrophy and permit fungus to thrive

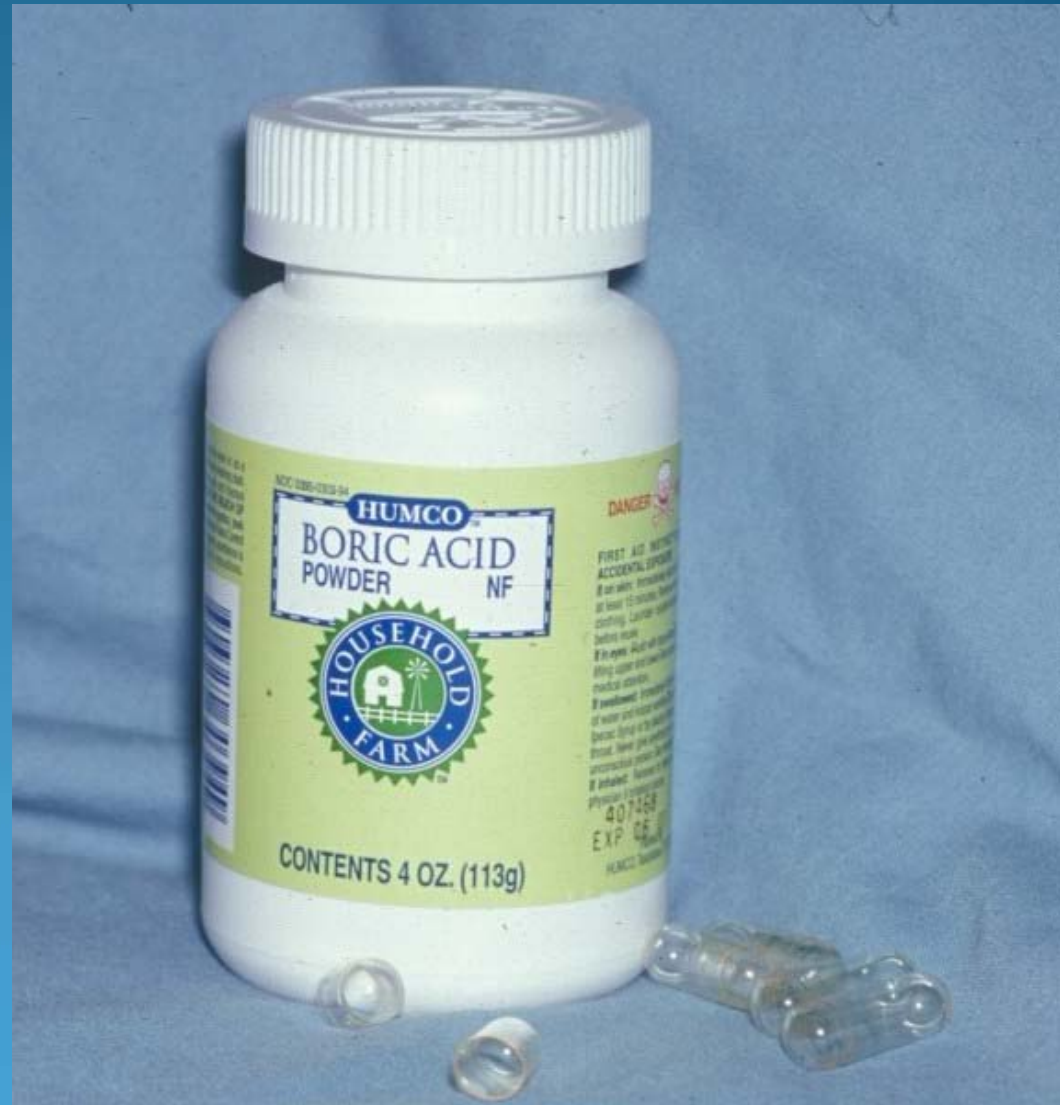
Majocchi's Granuloma

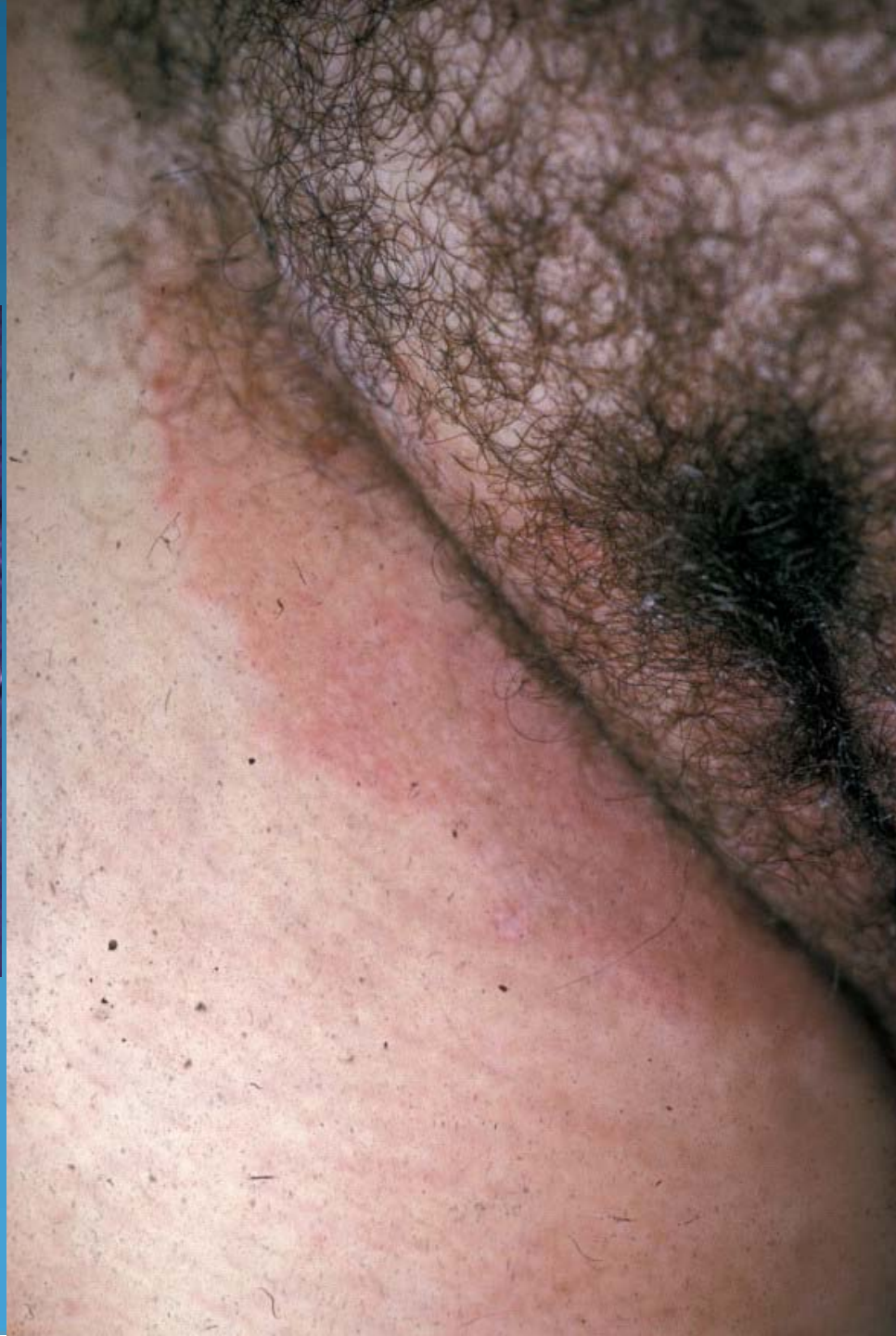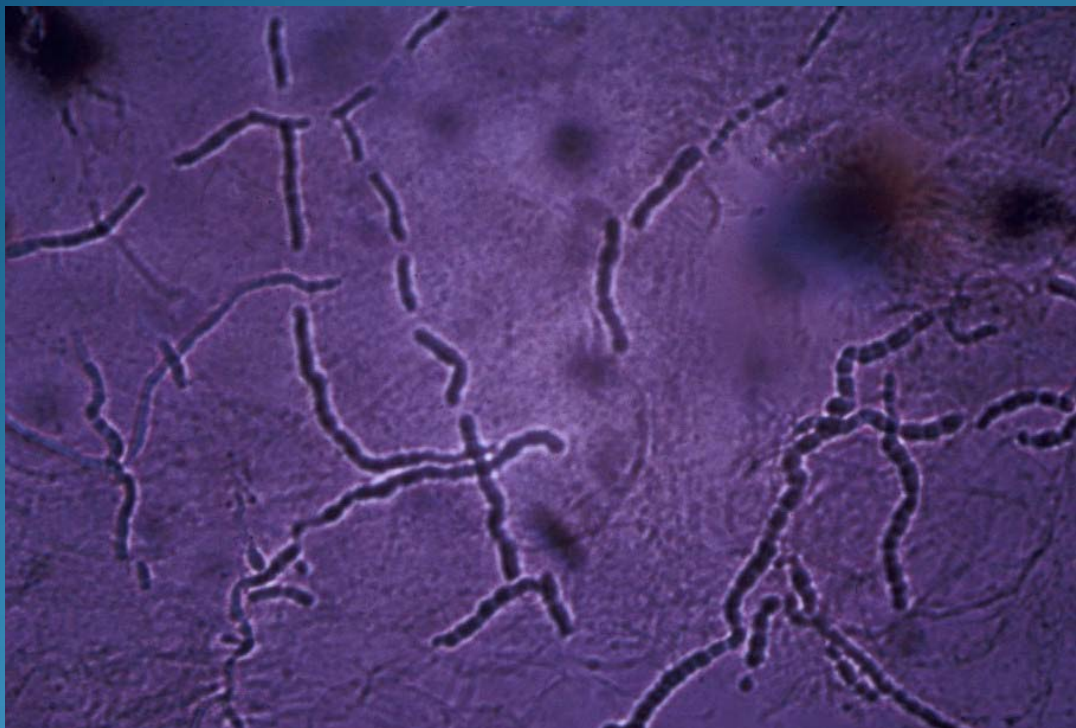


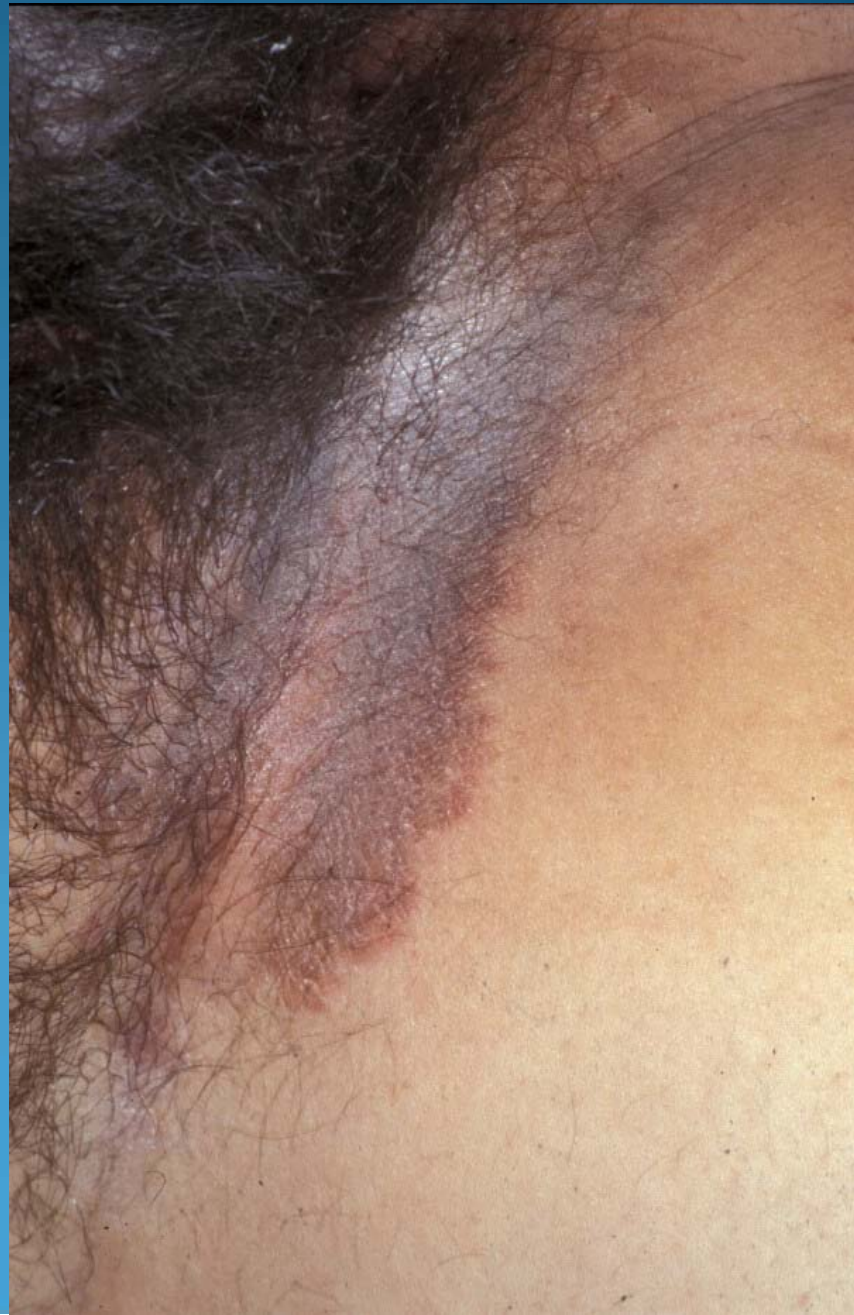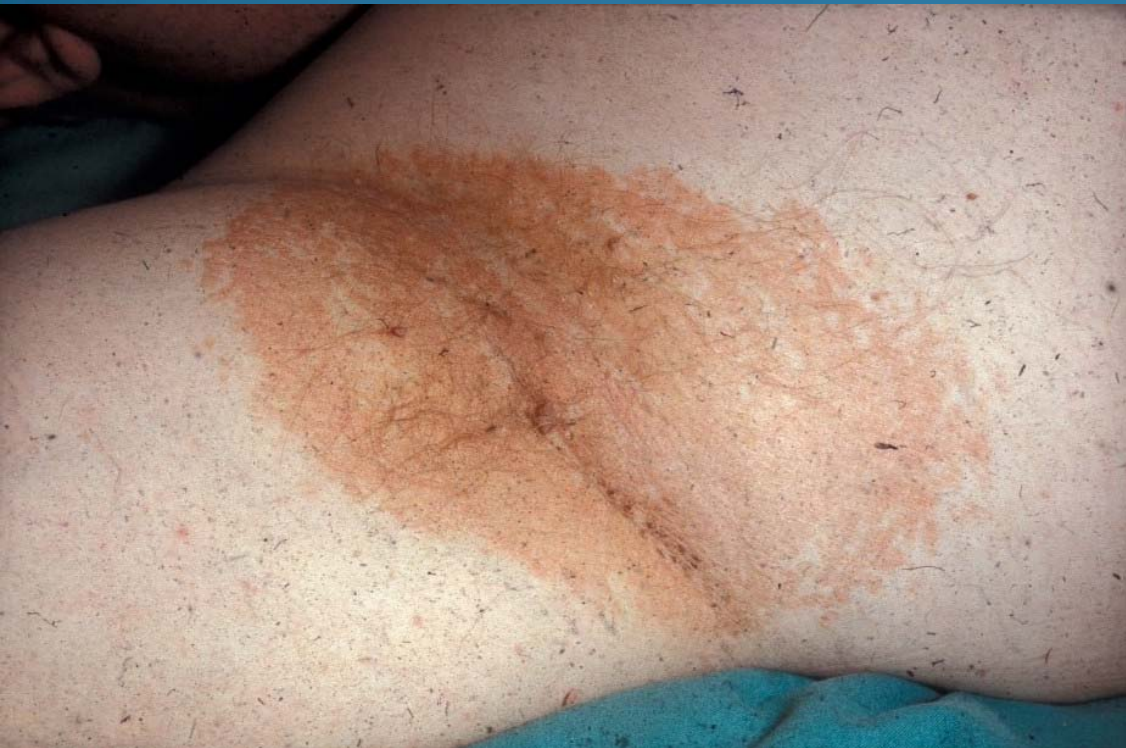Candida Rx

- If infection is recurrent or recalcitrant
- Diflucan 150-200mg q week for 2 weeks
 - Treat w/ Diflucan for 6 weeks
 - Add Boric Acid vaginal suppositories, 600mg two nights a week

Boric Acid



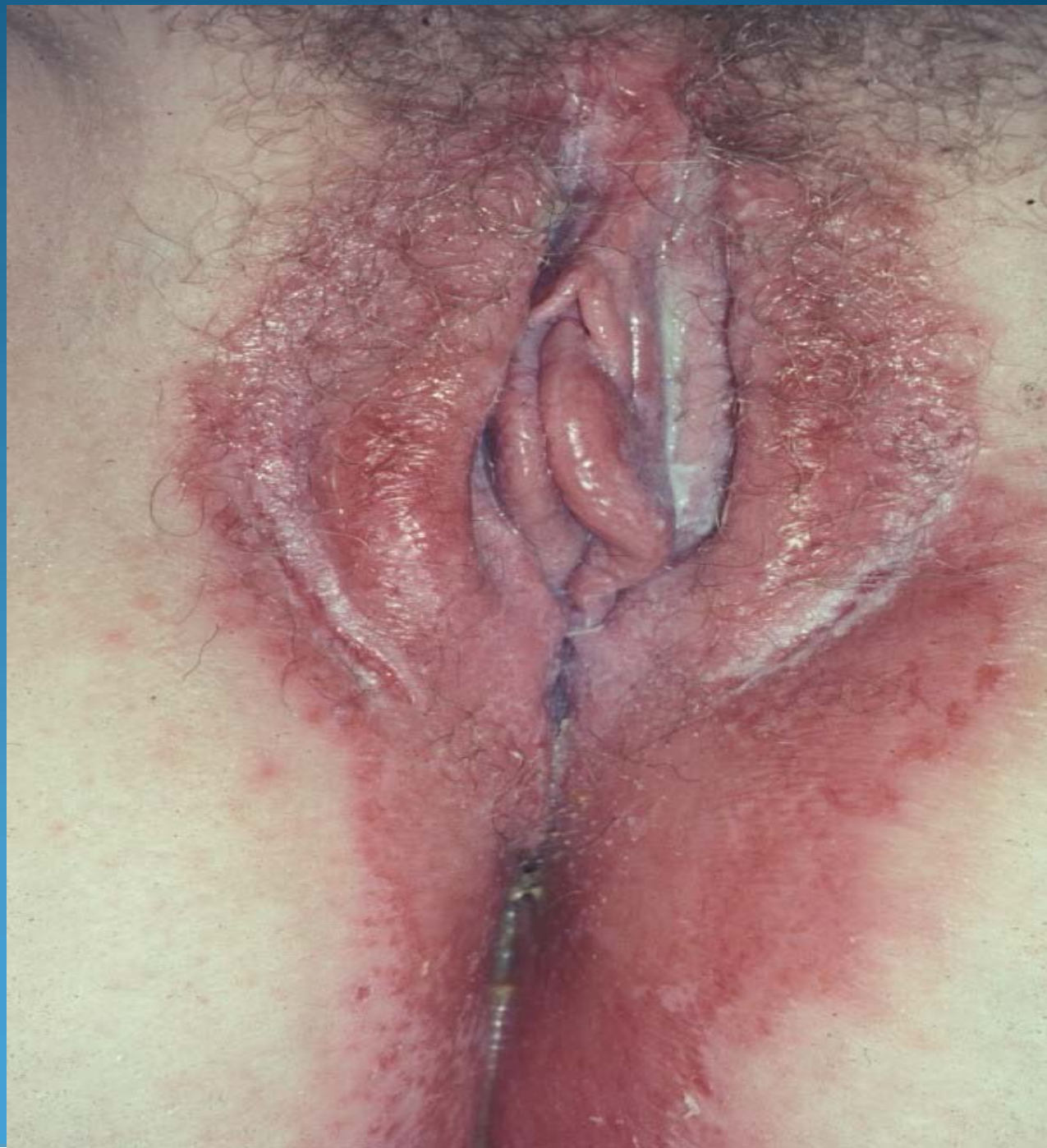





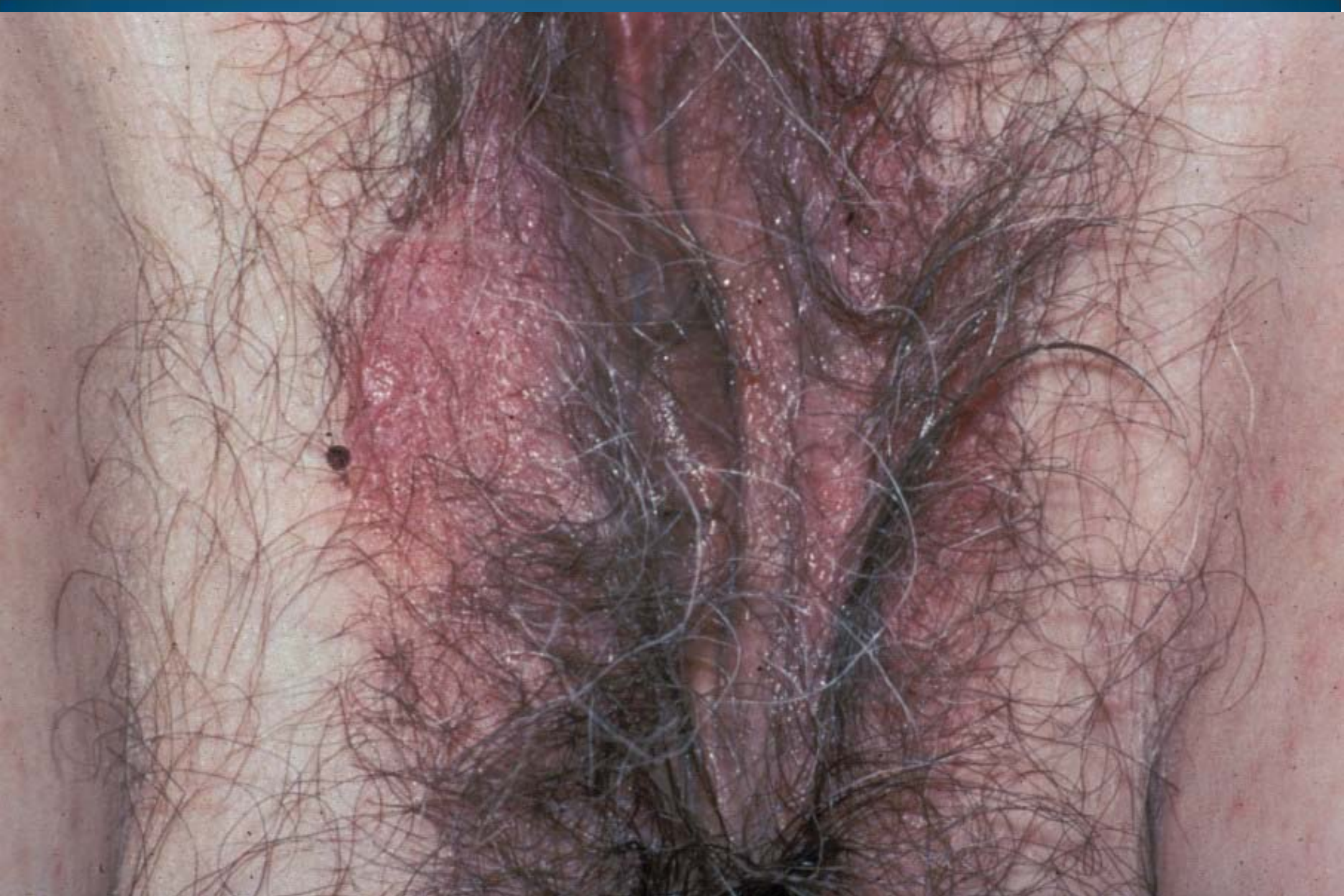
Erythrasma Treatment

- Oral Erythromycin 500mg bid x 2 weeks
- Topical Cleocin T Lotion bid x 2 weeks

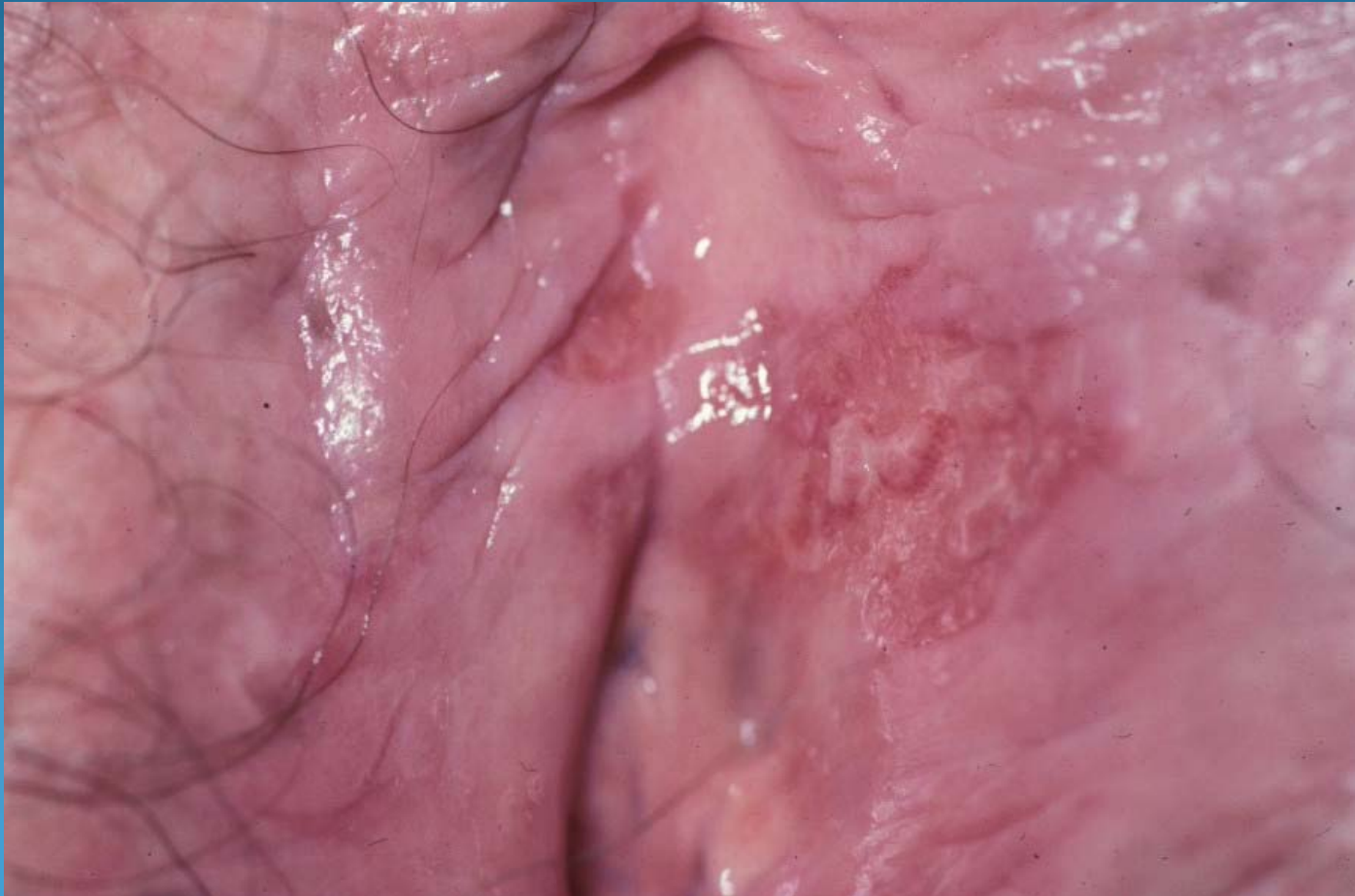


Work up and Rx

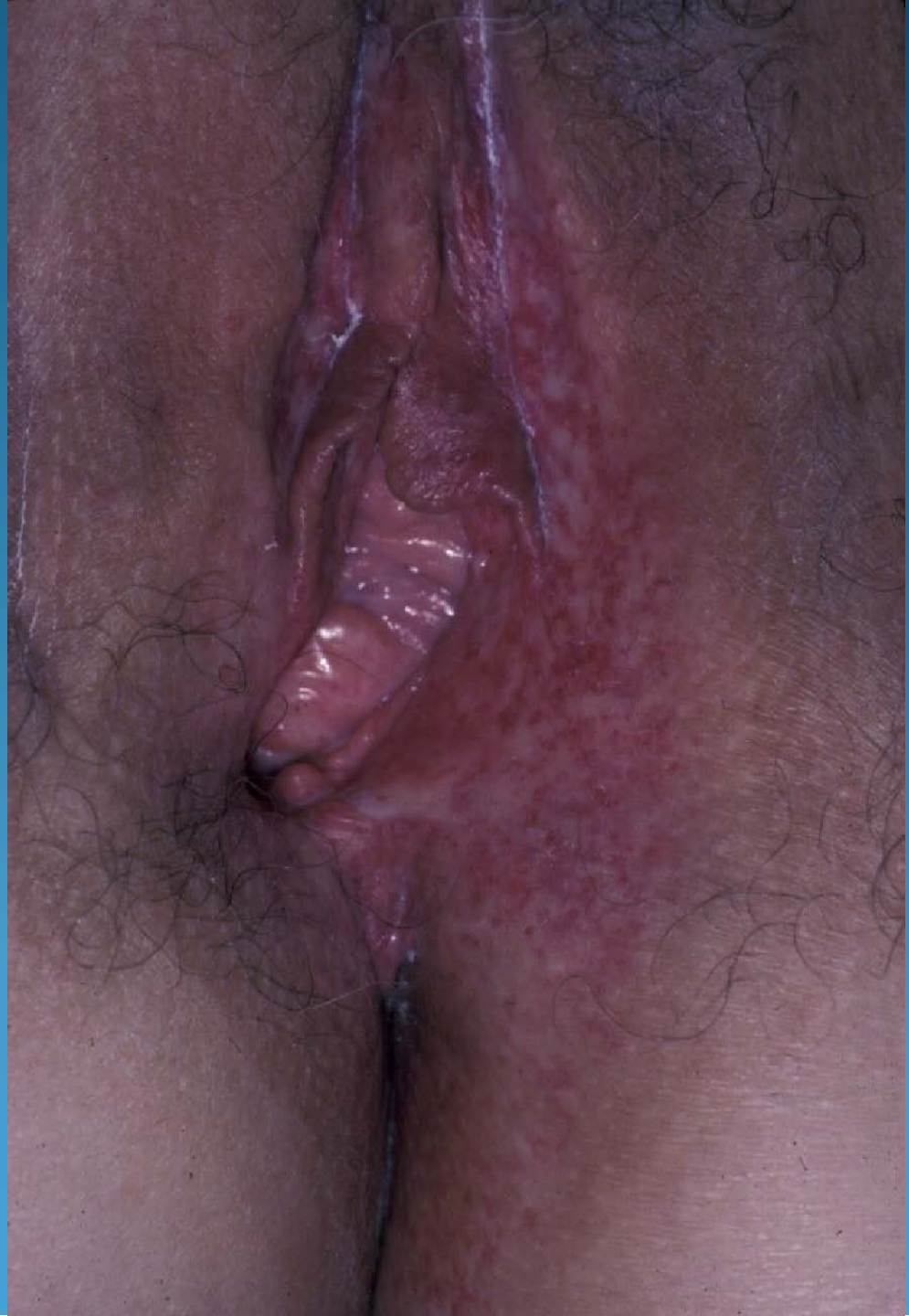- Hx and Px to look for clues
- KOH if scales or pustules
- KOH vaginal wall and send for yeast culture
- Stop all contactants
- Sitz baths followed by vaseline
- Bactroban or oral antibiotics for erosions
- Albolene for intercourse
- RTC in 6 weeks



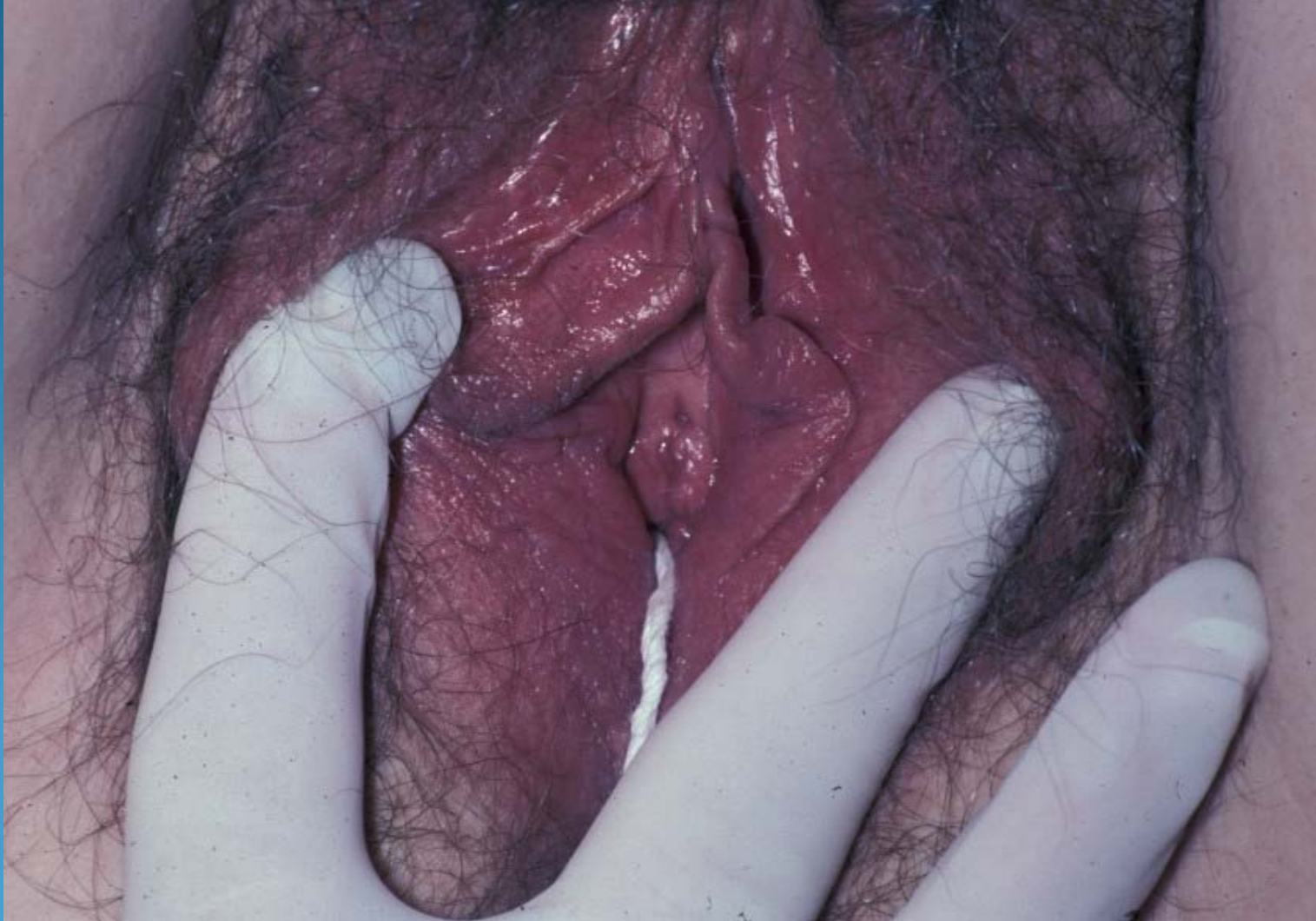Vulvar Intraepithelial Neoplasia



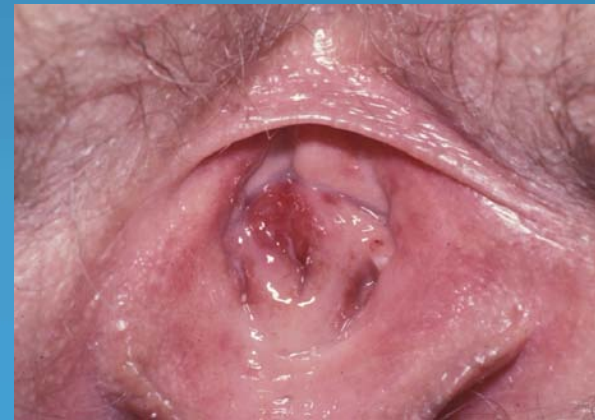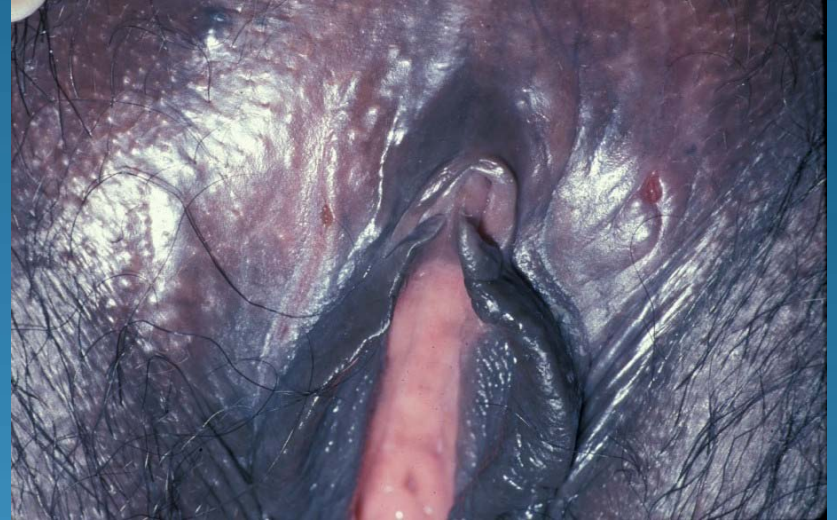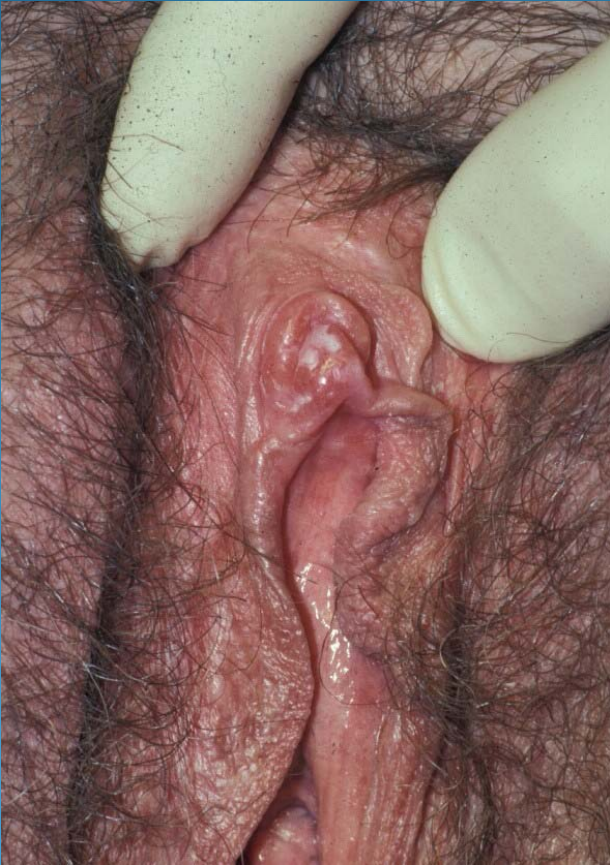Radiation Dermatitis



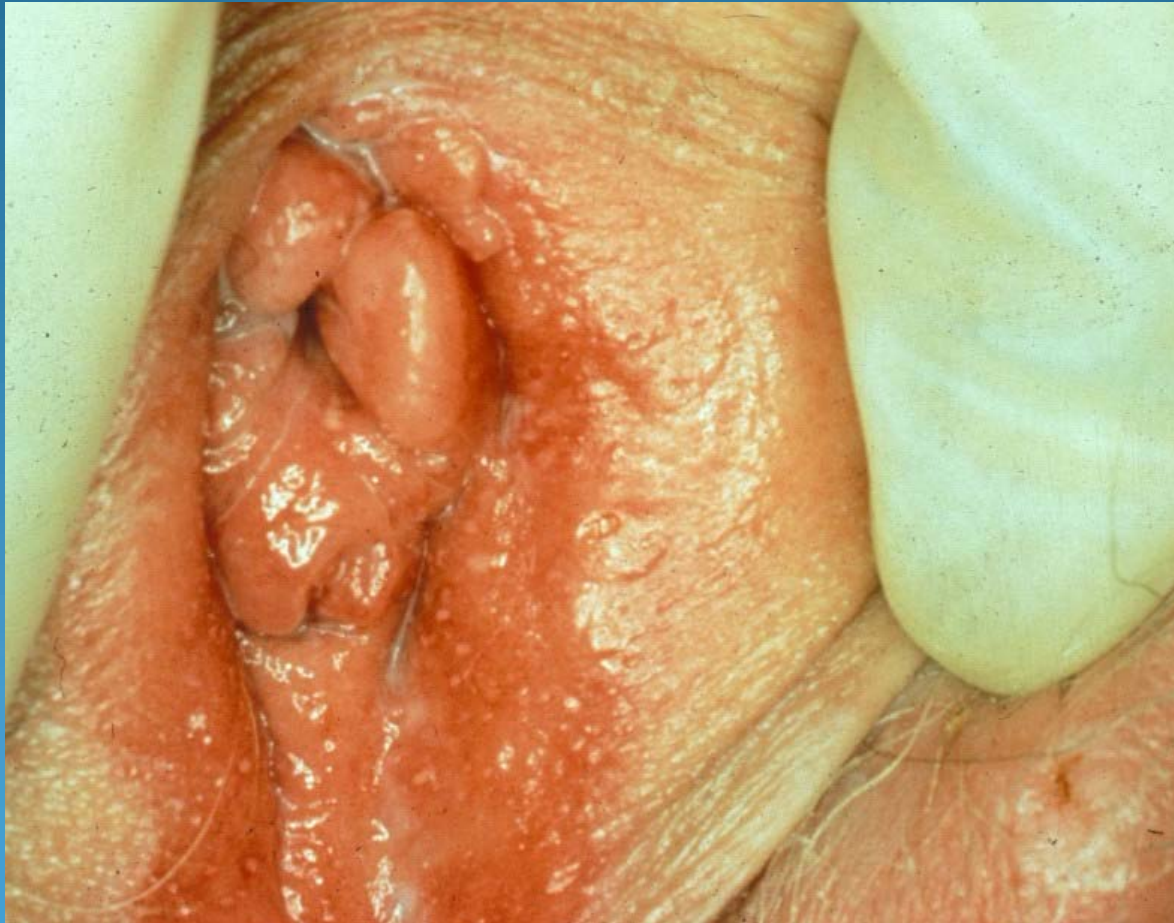Contact Dermatitis



Zoon's Vulvitis



ROSACEA



Paget's Disease

